

# Single Visit Apexification : A Novel Approach - A case report

Thapa Asha<sup>1</sup>, Gautam Suman<sup>2</sup>

<sup>1</sup>Assistant Professor, Dental Department.

<sup>2</sup>Assistant Professor, Department of Conservative dentistry & Endodontics

<sup>1</sup>NAMS, Bir Hospital

<sup>2</sup>Nepal Medical College

## INTRODUCTION

Success of endodontic treatment depends on adequately cleaned and completely sealed root canal space. Immature permanent teeth with pulpal necrosis represents a significant challenge in endodontic management because of the incomplete root development leaving behind the thin walled short root with wide apical opening usually greater in diameter than coronal portion.<sup>1-4</sup> The causes for pulp necrosis in immature teeth may be dental caries, trauma or the presence of dental anomalies like dens invaginatus, dens evaginatus etc.<sup>5</sup> Apexification with calcium hydroxide (CH) is a popular traditional way of non-surgical management of such cases<sup>1-8</sup>. At present single visit apexification and revitalization procedures are being applied more frequently in management of such cases.<sup>2-5</sup> This case deals with management of immature necrotic tooth with single visit apexification procedure. In this procedure apical plug is built with MTA or bioceramic materials against which the warm gutta percha is condensed.

## CASE REPORT

18 years old female patient came to the dental department with the complaint of discolored upper front tooth. Patient was not aware of any form of trauma to the tooth. On examination 21 was found to have grayish discoloration and was slightly tender to percussion. It was not responsive to cold test and electric pulp tester. There was no associated sinus opening. IOPA radiograph of 21 revealed short root, thin

dentinal wall and wide apical opening with associated periapical radiolucency.

On the first visit the access was made under rubber dam isolation and the canal was then gently cleaned with manual instruments and 3% NaOCl irrigation (Prime dental, India). The working length was measured radiographically with a K-file (Dentsply Maillefer, Switzerland). Then the canal was dried with absorbent paper point (Dentsply Maillefer, Switzerland) and CH (Prime dental, India) dressing was given. The orifice was sealed with sterile cotton pellet and temporary cement (Meta Biomed, Korea) was placed. Then the patient was recalled after 7 days.

On the next visit again under rubber dam isolation temporary cement was removed, CH was removed by rinsing with alternating solution of 3% sodium hypochlorite and 17% EDTA. A final rinse with normal saline was performed. Then the canal was dried with paper point (Dentsply Maillefer, Switzerland). MTA (Produits Dentaires SA, Switzerland) was mixed according to manufacturer instruction and taken to the canal with cement carrier and then condensed with the help of plugger of appropriated size with the stopper adjusted 4 mm short of root end. After 2-3 increment the sealing of the apex was verified radiographically and sterile cotton pellet moistened with distilled water was placed in the canal orifice and sealed with temporary cement (Meta Biomed, Korea). After 3 days the MTA plug was checked for hardening. Then the remaining of the canal was back-filled with injection-

Correspondence: **Dr. Asha Thapa**; e-mail: [ashathp@gmail.com](mailto:ashathp@gmail.com)

## Case Report

moulded thermoplastic gutta-percha (Meta Biomed,Korea) and resin sealer (Meta Biomed,Korea). On the same visit cervical barrier was made with glass ionomer cement (GC) for intra canal bleaching. The bleaching agent (Endo bleach,Ultradent,USA) was placed and closed with wet cotton and glass ionomer cement seal. The bleaching agent was changed in the interval of 48 hours for 3 visits and after noticeable shade change was observed the tooth was then restored with composite resin.

The patient visited the department after 3 years for the follow up visit. Patient did not give any history of pain or discomfort after her previous visit and the iopa radiograph taken at that time showed a good periapical healing.

### DISCUSSION

Apexification is defined as “a method of inducing a calcified barrier in a root with an open apex or the continued apical development of an incompletely formed root in teeth with necrotic pulp”.<sup>6</sup> The young pulpless tooth frequently has thin, fragile walls, wide opened apex usually greater in diameter than coronal pulp canal. This makes it difficult to clean adequately and obtain the necessary apical seal with conventional gutta percha method.<sup>13, 14</sup> Traditionally, such case has been managed by use of calcium hydroxide to induce apexification after disinfection of the root canals in the conventional manner. Filling the root canal was typically delayed until completion of root-end closure through apexification because without the barrier there is nothing against which the traditional gutta-percha filling material can be condensed.<sup>1-3, 5, 8, 13, 14</sup> The time required for apical barrier formation using (CH) may be as long as 20 months and other conditions such as age and presence of symptoms or periradicular radiolucencies may affect it <sup>5,14</sup>. Refreshing the CH paste usually takes place every 3 months.<sup>15</sup> A number of shortcomings has been identified with CH apexification which includes long time-span of the entire treatment, multiple visits with heavy demands on patients and carers, inevitable clinical costs, increased risk of tooth fracture

using CH as a long-term root canal dressing.<sup>7-14</sup> Other disadvantages of traditional, long-term CH therapy include variability in treatment time, unpredictability of formation of an apical seal, difficulty in following up patients, and delayed treatment.<sup>8</sup>

An alternative to CH therapy is placement of an apical plug. Mineral trioxide aggregate (MTA) is a material that may be best suited as an apical plug. Several studies have confirmed successful clinical outcomes including healing of existing periapical lesions in majority of immature teeth that were treated with an MTA apical plug.<sup>2-4</sup> Using MTA for apexification may shorten the treatment period with more favourable results and improved patient compliance.<sup>17,18</sup> Many authors and clinicians propose a one-visit apexification protocol with MTA, which presents a major advantage over traditional CH methods.<sup>19, 20</sup>

The shortcoming of single visit apexification, similar to CH therapy, is that placement of an apical plug does not account for continued root development along the entire root length.<sup>2</sup>Hence they are highly susceptible to fracture.<sup>7, 32</sup> Therefore, alternative approaches that allow the increase of root thickness and/or length should be pursued. Recently revascularization/revitalization procedures are suggested to apply in such cases to allow continued root development. However, revascularization treatment has comparable, but not superior, clinical and radiographic outcomes with traditional apexification procedures.<sup>21</sup>Although several studies have attempted to predict the timing of periapical wound healing, increased thickening of the canal walls, and continued root lengthening of immature permanent necrotic teeth after revascularization treatment, the expected rate of these outcomes remains unknown.<sup>29-31</sup> Since patient was going aboard shortly and had very limited time single visit apexification was chosen for the patient after explaining all the modalities of treatment.

In this case we have used CH as intra canal medicament before the placement of MTA

## Case Report

plug. The use of calcium hydroxide is still controversial.<sup>10</sup> Recent data suggest that the combination of MTA and calcium hydroxide in apexification procedures may favourably influence the regeneration of the periodontium.<sup>25</sup> However, some studies had shown that remains of calcium hydroxide that remain on the canal walls had no significant effect on MTA leakage<sup>21</sup> and another study had suggested that remnants of calcium hydroxide on the canal walls may react to form calcium carbonate, and interfere with the seal produced.<sup>23</sup> In the present work, complete removal of calcium hydroxide from the canal walls was accomplished by alternate irrigation with 3% NaOCl and 17% EDTA and normal saline.<sup>24</sup>

The type of intracanal delivery technique may contribute to the final success of treatment in one visit apexification.<sup>26</sup> In the present study, the MTA apical plug was placed by a standardized hand condensation technique. In a laboratory study hand condensation resulted in better adaptation and fewer voids than ultrasonic compaction.<sup>27</sup> Hence in this case also hand condensation method was applied.

The thickness of apical MTA plug has not found to influence the apical leakage rather it has been found to directly impact the displacement resistance.<sup>28,29</sup> In the present study, the thickness of the MTA apical plug was 6mm.

Intracanal bleaching is the most conservative way of managing discolored tooth. Hence bleaching is carried out in this case for discoloration management. Coronal restoration is done with composite following the achievement of desired tooth color. It is believed that the bonded restoration up to the cervical level of the tooth managed with single visit apexification will strengthen and prevent potential fractures of immature teeth.<sup>2,3,14,17,19,21</sup>

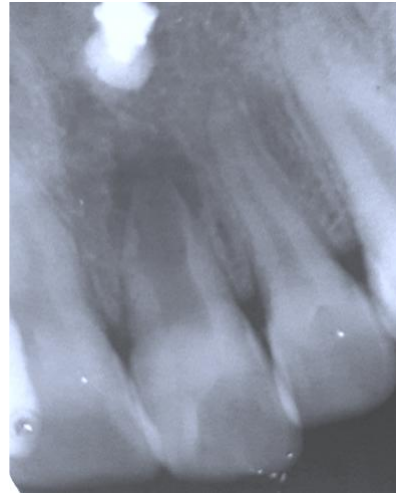


Figure 1 : Preoperative IOPA

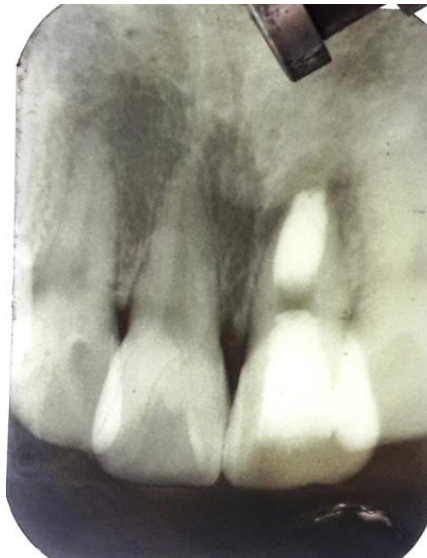

Figure 2: Immediate postoperative

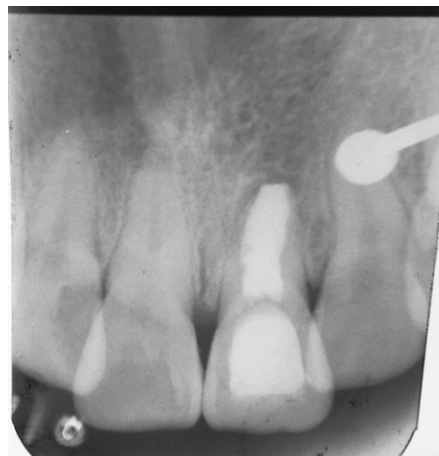

Figure 3: Recall IOPA after 3years

### CONCLUSION

Single visit apexification and intracoronal bleaching can be one of best conservative problem in management of discolored necrotic immature tooth.

### REFERENCES

1. Frank AL. Therapy for the divergent pulpless tooth by continued apical formation. *American dental association* 1966; 72:87–93.
2. Shabahang S. Treatment Options: Apexogenesis and Apexification. *J Endod* 2013; 39:S26–S29.
3. Simon S, Rilliard F, Berdal A, Machtou P. The use of mineral trioxide aggregate in one-visit apexification treatment: a prospective study. *International Endodontic Journal*, 2007; 40: 186–197.
4. Felipe WT, Felipe MCS, Rocha MJC. The effect of mineral trioxide aggregate on the apexification and periapical healing of teeth with incomplete root formation. *International Endodontic Journal* 2006;39:2–9.
5. Flanagan TA. What can cause the pulps of immature, permanent teeth with open apices to become necrotic and what treatment options are available for these teeth. *Aust Endod J* 2014; 40: 95–100.
6. AAE (2003) Glossary of endodontic terms. Chicago: American Association of Endodontists.
7. Cvek M. Prognosis of luxated non-vital maxillary incisors treated with calcium hydroxide and filled with gutta-percha. A retrospective clinical study. *Endodontics and Dental traumatology*1992; 8:45–55.
8. Huang GT. Apexification: the beginning of its end. *International Endodontic Journal* 2009; 42: 855–866.
9. Andreasen JO, Farik B, Munksgaard EC. Long-term calcium hydroxide as a root canal dressing may increase risk of root fracture. *Dental Traumatology* 2002; 18: 134–7.
10. Andreasen JO, Munksgaard EC, Bakland LK. Comparison of fracture resistance in root canals of immature sheep teeth after filling with calcium hydroxide or MTA. *Dental Traumatology* 2006; 22: 154–6.
11. Chosack A, Sela J, Cleaton-Jones P. A histological and quantitative histomorphometric study of apexification of nonvital permanent incisors of vervet monkeys after repeated root filling with a calcium hydroxide paste. *Endodontics and Dental Traumatology* 1997; 13: 211–7.
12. Dominguez RA, Munoz ML, Aznar MT. Study of calcium hydroxide apexification in 26 young permanent incisors. *Dental Traumatology* 2005; 21: 141–5.
13. Ingle JJ, Bakland LK. *Endodontics*. 5th ed. Hamilton: BC Decker Inc;2002. 405-570.
14. Ingle JJ, Bakland LK. *Endodontics*. 6<sup>th</sup> ed. Hamilton: BC Decker Inc;2006.
15. Rafter M. Apexification: a review. *Dental Traumatology*2005;21: 1–8.
16. Shabahang S, Torabinejad M, Boyne PP, Abedi H, McMillan P. A comparative study of root-end induction using osteogenic protein-1, calcium hydroxide, and mineral trioxide aggregate in dogs. *Journal of Endodontics* 1999; 25: 1–5.
17. Maroto M, Barberia E, Planells P, Vera V. Treatment of a non-vital immature incisor with mineral trioxide aggregate (MTA). *Dental Traumatology* 2003;19: 165–9.
18. El-Meligy OA, Avery DR. Comparison of apexification with mineral trioxide aggregate and calcium hydroxide. *Pediatric Dentistry* 2006; 28: 248–53.
19. Steinig TH, Regan JD, Gutmann JL . The use and predictable placement of mineral trioxide aggregate in one visit apexification cases. *Australian Endodontic Journal* 2003; 29:34–42.
20. Pace R, Giuliani V, Pini Prato L, Baccetti T, Pagavino G. Apical plug technique using mineral trioxide aggregate: results from a case series. *International Endodontic Journal* 2007; 40:478–484.
21. Alobaid AS, Lina M, Cortes LM, Lo J. Radiographic and Clinical Outcomes of the Treatment of Immature Permanent Teeth by Revascularization or Apexification: A Pilot Retrospective Cohort Study. *Journal of Endodontics* 2014;40:1063–1070.
22. Hachmeister DR, Schindler G, Walker WA, Thomas DD. The sealing ability and retention characteristics of mineral trioxide aggregate in a model of apexification. *Journal of Endodontics* 2002; 28:386–90.
23. Porkaew P, Rettief H, Barfield RD, Lacefield WR, Soon S. Effects of calcium hydroxide paste as an intracanal medicament on apical seal. *Journal of Endodontics*1998; 24:176–179.
24. Calt S, Seper A. Dentinal tubule penetration of root canal sealers after root canal dressing with calcium hydroxide. *Journal of Endodontics* 1999;25:431–433.
25. Ham KA, Witherspoon DE, Gutmann JL, Ravindranath S, Gait TC, Opperman LA.

## Case Report

- Preliminary evacuation of BMP-2 expression and histological characteristics during apexification with calcium hydroxide and mineral trioxide aggregate. Journal of Endodontics* 2005; 31: 275–279.
26. Al-Kahtani A, Shostad S, Schifferle R, Bhambhani S. In-vitro evaluation of microleakage of an orthograde apical plug of mineral trioxide aggregate in permanent teeth with simulated immature apices. *Journal of Endodontics* 2005; 31:117–119.
  27. de Leimburg ML, Angeretti A, Ceruti P, Lendini M, Pasqualini D, Berutti EMTA obturation of pulpless teeth with open apices: bacterial leakage as detected by polymerase chain reaction assay. *Journal of Endodontics* 2004; 30: 883–6.
  28. Hachmeister DR, Schindler G, Walker WA, Thomas DD The sealing ability and retention characteristics of mineral trioxide aggregate in a model of apexification. *Journal of Endodontics* 2002; 28:386–90.
  29. Bose R, Nummikoski P, Hargreaves K. A retrospective evaluation of radiographic outcomes in immature teeth with necrotic root canal systems treated with regenerative endodontic procedures. *Journal of Endodontics* 2009; 35:1343–1349.
  30. Diogenes A, Henry MA, Teixeira FB, Hargreaves KM. An update on clinical regenerative endodontics. *Endodontic Topics* 2013; 28:2–23.
  31. Jeeruphan T, Jantarat J, Yanpiset K. Mahidol study 1: comparison of radiographic and survival outcomes of immature teeth treated with either regenerative endodontic or apexification methods: a retrospective study. *Journal of Endodontics* 2012; 38:1330–6.
  32. Katebzadeh N, Dalton BC, Trope M .Strengthening immature teeth during and after apexification. *Journal of Endodontics* 1998 Apr; 24(4):256-9.