

Lightening dark dental radiograph

Shakya S¹, Ongole R², Sumanth KN³

¹Specialist Resident, ²Associate Professor, ³Professor, Department of Oral Medicine and Radiology, Manipal College of Dental Science, Mangalore.

Abstract

Radiograph should be of diagnostic quality for proper diagnosis. Dark radiographs are most commonly encountered faults in dental radiography which renders the radiograph useless. Such faulty radiograph requires a retake of the radiograph which causes unnecessary exposure to the patient and waste of precious time. Hence, a simple method is required which could salvage a dark radiograph. This article describes various methods used for lightening a dark radiograph along with a simple method like scraping the emulsion.

Key words: Dark radiograph, Double emulsion films

Introduction

Radiographs with a diagnostic quality aids in the accurate diagnosis of the lesions. Dark radiographs are one of the various radiographic faults encountered in the daily dental practise resulting in an image with low diagnostic quality which requires a need for an additional exposure to the patient. With the increasing concern of radiation protection and safety it would be better if a technique is developed wherein the dark radiograph can be lightened enough to be of diagnostic quality.

Various methods have been used for lightening a dark radiograph which has been darkened due to reasons like increased exposure or the increased developing time but surprisingly these techniques have been lost from text books may be with the invent of digital imaging techniques. However conventional film radiography is still in use. Some techniques that have been used are discussed here. This article attempts to review the various techniques that have been used.

Levin B et al (1990) described a simple technique for lightening dark radiograph. This technique used house hold bleach or hydrogen peroxide for 5 min on one side of the film in a double emulsion film and removing the emulsion using stiff brush or non metallic pot cleaner. The disadvantage of this method is any bleach reaching the second emulsion will remove the entire picture¹.

Kaplan I et al (1990) used superproportional reducing agent for lightening dark radiograph. They used copper sulphate, sodium chloride, and sulphuric acid. The superproportional reducing agents removes silver ions in the proportionate manner that is more from the darker area and less from light areas from the film thus leading to image of good diagnostic quality with increased resolution, decreased density. The prepared bleach solution has good shelf life but, the disadvantage is the colour that occurs on the radiograph².

Kumar et al (1991) described a technique which was originally described by Farmer in 1884. This requires the use of mixture of 1 part of potassium ferricyanide (75 g of potassium ferricyanide crystals to make 1,000 mL) and 4 parts of sodium thiosulfate (240 g of sodium sulfate crystals to make 1,000 mL) mixed with 27 parts of water. Potassium ferricyanide reacts with the silver of the radiograph to produce silver ferricyanide which is soluble, thus removed from the film by the action of thiosulfate. This procedure can be repeated any number of times as required and can be done in the lights. It can also be used for ultrasound and computed tomographic images. The disadvantage of this procedure is the use of dangerous agents, cyanide and the prepared solution has a short shelf life around 30 min³.

Correspondence

Dr. Shrijana Shakya, Department of Oral medicine and Radiology, Manipal College of Dental Science, Mangalore.
E-mail: shriju79@hotmail.com

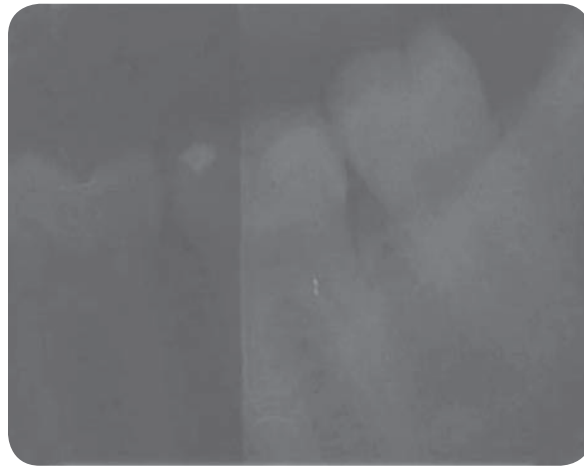


Fig. 1: Right half of the radiograph is scrapped and lightened.

Ok HK et al (1992) introduced a simple technique in which increasing exposure time in film duplicator allows production of duplicate radiograph of appropriate diagnostic ability such that the image detail is improved without damage to original radiograph⁴.

Winstanley TD et al (1996) described a technique originally described by Wakefield in 1970, with a very long shelf life. The method has been modified for ease in use. He describes the use of solution made of copper sulphate crystals (5ml), sodium chloride (5ml), Conc. hydrochloric acid (5ml), water (200ml) mixed in an old tea cup or beaker. This solution has very long shelf life. To lighten a dark radiograph it is soaked in water to make it soft, it is then rinsed in the reducing solution until the required density is obtained, washed, fixed and then dried. If over reduction occurs the film can be developed in the normal developing solution, re-reduced, and then fixed to obtain an diagnostic image⁵.

Beside, all these procedures that have been used for lightening the dark radiograph one of the easiest method would be scraping of the emulsion on one side. As, we all know that the double emulsion film has emulsion coat on both the sides of the film one side can be reduced by using a blade. The film need to be dipped in water for

sometime which allows the emulsion to be soft and aids in scraping. This procedure as described above does not require handling of chemicals and can be performed easily in any clinical or hospital setting. The radiograph lightened by this process is shown below.

Hence, there are various processes of lightening the dark film avoiding the retake of the radiograph if the dark film is the result of the overexposure or longer processing time. Among these some require use of chemical or mechanical procedure. The simplest one being the scraping of the emulsion on one side.

References

1. Levin B. Lightening Dark Double-Emulsion Radiographs. *Radiology* 1990;174:574.
2. Kaplan I, Dickens RL. Lightening of Dark Radiographs with a Superproportional Reducing Agent. *Quintessence International* 1990;21(9):737-40.
3. Kumar R, Saha MM. Lightening Dark Radiograph (letter). *Radiology* 1991;178(2):583.
4. Ok H K, Myeong I A, Yong W B. Use of Film Duplicator to Lighten Dark Radiographs' *Radiology* 1992;184(2):573
5. Winstanley TD. Salvaging Dark Dental Radiographs. *Dental Update*1996;23(6):246-9.