

VARIATIONS IN THE ROOT-CANAL MORPHOLOGY :

A CASE REPORT OF 2 MANDIBULAR INCISORS.

Dr. Ravi Pant & Dr. Samir Gharti, Dental Surgeons
People's Dental college & Hospital, Nayabazar, Kathmandu

ABSTRACT:

Anatomy of the pulp space is the most complex one & the variations are encountered when one least expects them. In most cases the number of root canals corresponds with the number of roots, but a root may have more than one canal.

KEYWORDS:

Rootcanal morphology, attrition, rootcanal therapy, biomechanical preparation, obturation.

INTRODUCTION:

“Of all the phases of anatomic study in the human system, one of the most complex is that of the pulp cavity morphology”¹.

In most cases, the number of root canals corresponds with the number of roots, but a root may have more than one canal. The mesial root of the mandibular 1st molar almost always has two canals (93.3%)², the distal root of the mandibular 1st molar occasionally has two canals (28.9%)²; the mesiobuccal root of the maxillary 1st molar sometimes has two canals (51.5%)³ & even the pulp cavity of a mandibular anterior tooth may be bifurcated, to present two separate root canals, one such case with two mandibular incisors having two root canals is reported in this paper.

CASE REPORT:

In the department of conservative dentistry & endodontics of PDCH, Nayabazar, a 52 years old male presented with the chief complaint of pain in

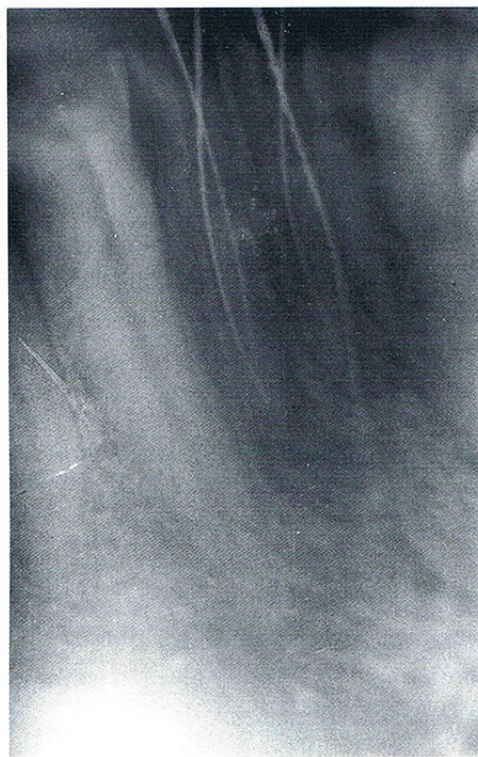


Figure 1: Determination of working length

lower anterior region. On examination severe attrition of 31 & 32 was found, sensitivity to exploration and tenderness to percussion was evident clinically. An IOPA radiograph was taken to reveal attrition in close approximation to the pulp and slight periapical changes.

Patient was explained about the nature of the problem and the treatment required. Root canal therapy was initiated accordingly.

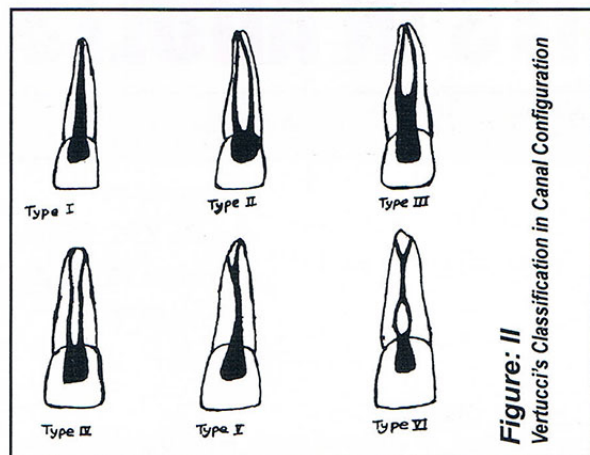


Figure: II
Vertucci's Classification in Canal Configuration

Access cavity was prepared in both 31 and 32 under local anaesthesia and pulpal remnants were removed with barbed broach. Pulp chamber was flushed copiously with sodium hypochlorite solution then

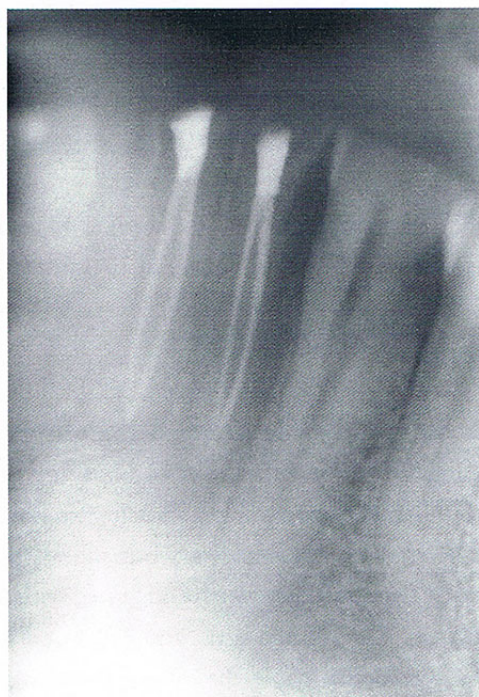

Figure: II
Obturation completed & Zinc Phosphate interim restoration placed

was & RC-prep filled in the chamber. Initial biomechanical preparation (BMP) with 15 & 20 size H files was carried out & cresophene close dressing was given. In the next appointment working length was established using Grossman's formula (figure 1). Interestingly both 31 & 32 had two canals, that were existing in the single apical

foramen [Vertucci's type II canal (figure II)].

In subsequent visits BMP was completed using H-files & NiTi files, along with copious irrigation with sodium hypochlorite and normal saline in a step back manner. Studies have shown that hydrogen peroxide offers no added benefits and need not be included⁴. Finally obturation was completed with Gutta percha and endomethasone root canal sealer and Zinc phosphate interim restoration placed (figure III). Later permanent restoration with composite resin was done and patient presented no further problems.

DISCUSSION:

The mandibular central incisor has one root, which is flat & narrow mesiodistally but wide labiolingually. The root is straight in 60% of cases, or it may have a distal (23%) or labial (13%) curvature⁵. The canal configuration varies from 1 canal existing in 1 apical foramen (70%), 2 canals exiting in 1 apical foramen (5%), or 1 canal bifurcating into 2 canals, coming together, & exiting into 1 apical foramen (22%) conversely, 2 canals may exit into 2 apical foramina (3%)⁶.

The root of the mandibular lateral incisor is larger than that of the mandibular central incisor, but it follows the same basic configuration.

Therefore, it is important however, from a dentist's point of view to always look for some unusual finding in pulp chamber he has opened, for unexpected will reveal itself when it may be most unwelcome.

REFERENCES:

1. Barret, M.T : Dent. Cosmos. 67 : 581, 1925
2. Skidmore, A.G. & Bjorndahl, A.M. Oral surg, 32:778, 1971
3. Weine, F. et al : Oral Surg. 28 : 419, 1969
4. Svec, T. A. Harison J.W. Journal of endodontics, 3 :49, 1977
5. Ingle, J.I & Taintor, J.E. Endodontics, 3rd edition, Philadelphai, Lea & Febiger, 1985.
6. Vertucci, F.J. Oral Surg., 58:589, 1985