

# \* PATTERN OF LINGUAL FRENUM AND ITS ROLE IN ESTABLISHING INCISAL LEVEL OF MANDIBULAR CENTRAL INCISORS DURING VERTICAL DIMENSION

Dr. Suraj Ram Bhakta Mathema, MDS

HOD, Dept. of Prosthodontist

People's Dental College & Hospital, Naya Bazar, Kathmandu, Nepal.

## INTRODUCTION

Determination of the correct vertical dimension for occlusion and the proper vertical positioning of the anterior teeth in the edentulous arch are interrelated to each other to fabricate a functionally, esthetically and phonetically pleasing complete denture prosthesis. Positioning the level of upper and lower anterior teeth is subjected to many variables and is mostly based on clinical judgments and experience.

Many methods have been proposed to determine the correct vertical dimension for occlusion. These include the use of inter-occlusal distance<sup>18</sup>, swallowing<sup>20</sup>, patients neuromuscular judgment<sup>14</sup>, knowledge of the utilisation of maximum masticatory force<sup>4</sup>, closest speaking space<sup>21</sup>, cephalometric radiographs<sup>7</sup>, intra and extra oral anatomic land marks<sup>9</sup> and phonetics. Use of reliable preextraction records have also been advocated for several years and many methods are suggested for its utilization. Among these are special gauges (Willis<sup>26</sup>, Sorenson<sup>23</sup>, Dakometer<sup>23</sup>), Cardboard and wire profiles<sup>1,17</sup>, measurements from photographs<sup>29,23</sup>, measurement of interfrenal distance<sup>23</sup>, measurements between tattoo marks on gingiva<sup>22,23</sup> and mounted pre-extraction casts<sup>11</sup>. In spite of these, there is no universally acceptable accurate method because of the variation in the physical characteristics of individuals.

In the maxilla, the incisive papilla is regarded as a stable anatomical land mark and therefore has been generally used to determine the level of upper anterior teeth in edentulous patient. If the distance between the incisive papilla and incisal edges of maxillary central incisors is measured on

a pre-extraction cast, then the vertical position of the maxillary central incisors in the edentulous patient can be copied<sup>30</sup>.

In the lower jaw, there are two anatomical anterior landmarks such as labial and lingual frenum, which can also serve as a reference to establish the height of incisal plane of mandibular anterior teeth. Among these two reference landmarks, the position of lingual frenum is more stable and can be accurately recorded. When compared to the other stable anatomical land marks, the Prosthodontic importance of lingual frenum has not been adequately exploited nor its morphological features described. From the view point of its location in midline area and its unaltered position, after the extraction of lower anterior teeth, it could serve well as a reference land mark in an edentulous person to orient the height of incisal plane of lower central incisors, if a relation between this structure and the incisal level of lower anterior teeth in the edentulous state can be studied.

Keeping this mind, this study was undertaken to primarily study the morphological features and pattern of lingual frenum of lower jaw, and then relate this structure in a vertical direction to the incisal level of mandibular central incisors in young adults so that any information obtained between them could be favorably used to establish the height of the incisal plane in lower anterior teeth in complete denture prosthesis.

## MATERIALS AND METHOD

### Source of Data

I. A sample of 50 subjects (25 males, 25 female) between age of group 20-35 years were

\*Abstracted from a thesis presented in partial fulfilment of the requirements for the award of the degree of Master of Dental Surgery (MDS) in the Faculty of Prosthodontics of the Rajiv Gandhi University, Bangalore, India.

selected. For the convenience of study, students and patients of A.B.Shetty Memorial Institute of Dental Sciences, Mangalore, Karnataka in this age group were selected for this purpose.

### Criteria for selection of subjects

1. Angle's Class I relationship
2. Having regular alignment of lower anterior teeth
3. Did not show ankyloglossia
4. Having prominent attachment of lingual frenum anteriorly in the midline.
5. Did not have carious, fractured, abraded or chipped of the incisal edges of any of the anterior teeth.
6. Did not have any restoration of anterior teeth.
7. Did not have congenital or developmental anomalies.
8. Did not have history of orthodontic treatment
9. Did not have mobility of anterior teeth

### Method of collection of data

Three mandibular impressions were made of each subject from irreversible hydrocolloid impression material using perforated mandibular stock tray which was adjusted by plieing and trimming so that anteriorly, the lingual edge of the tray did not impinge or interfere the tongue by keeping a minimum distance of 2-3mm from movable tissues of the floor of the mouth. (fig 1).

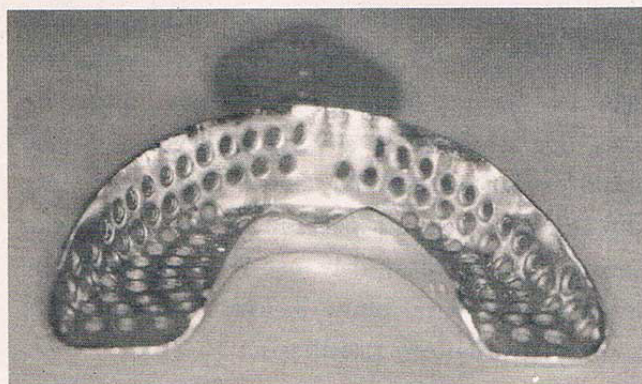


Fig. 1: Customised stock perforated mandibular tray

All subjects were instructed to elevate the tongue and moisten the upper lip with the tip of the tongue and hold it while the impression was made. Master cast were obtained by pouring with stone plaster. Materials used were of same batch and

manufacturer's instructions were strictly followed to standardized the procedures.

### Recording Procedures

Casts thus obtained were point marked by sharp carbon marker tip mounted on dental cast surveyor (fig.2), one on distoincisal edge of right

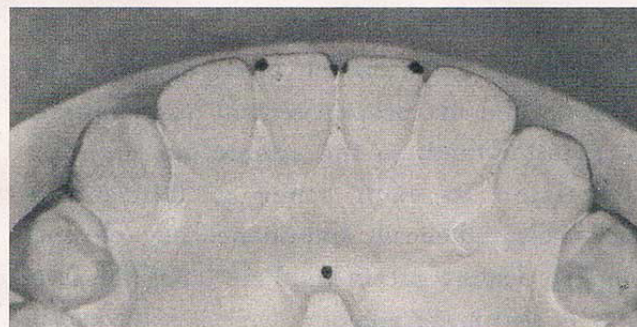


Fig. 2: Marking over the cast

central incisor, one on the midline and one on the distoincisal edge of left central incisor. The mean of these marks indicated the level of incisal edges of mandibular central incisors. Similarly one more mark was made on the anterior most point of the attachment of lingual frenum at the midline in the sublingual sulcus. All the marks were placed at the same position on all three casts of each subject. For the purpose of standardization three recordings were done on each cast.

The cast was then mounted on the cast holder of a dental surveyor with the occlusal plane located in horizontal position. To standardized the three casts of each subject at the same horizontal tilt on the cast holder of the surveyor, a device consisting




Fig. 3: Dental cast surveyor with acrylic device

of an acrylic plate with metal rod attached to its centre at 90 degree was made (fig.3). This method ensured that all the three casts were measured with its occlusal plane parallel to the base of the surveyor.

The acrylic device was replaced with the analyzing rod. The surveying arm with analyzing rod was lowered until the tip of the analyzing rod contacted the mark on the anterior most attachment of lingual frenum. A thin and sharp horizontal mark was made with a point mark pen where the upper end of the surveying arm meet the horizontal arm. Similarly, a second horizontal mark was placed on the upper end of the surveying arm when tip of the analyzing rod contacted each marks on the incisal edge of central incisors. The distance between two horizontal marks on the upper end of the surveying arm was measured by using a caliper with vernier scale up to the tenth of mm




Fig. 5: Vernier calliper being used to measure the distance

This distance between lower line and upper line on the surveying arm (Fig.5) represent the distance between anterior attachment of lingual frenum and incisal edge of mandibular central incisors.




Fig. 4: Dental cast surveyer being used to measure the distance

In this manner, measurements were obtained for three casts of each subject(fig 4). A total of 450 readings were made. This constituted the basic data for the study. The mean and standard deviation of the three measurements for all subjects were calculated and statistically analyzed.

II. For purpose of classification of lingual frenum, 500 dentulous and 100 edentulous subjects were randomly examined from the students and patients visiting A.B. Shetty Memorial Institute of Dental Sciences, Deralakatte, Mangalore to ascertain their anatomical features of lingual frenum attachment namely

1. Single band
2. Triple band
3. Multiple band

## RESULTS

Total 450 readings collected as basic data in respect of distance between anterior attachment of lingual frenum and incisal edges of mandibular central incisors and 600 data collected for the study of anatomical form of lingual frenum were tabulated and analyzed as follows:

### Table I:

Shows the minimum, maximum and mean distance between anterior attachment of lingual frenum and incisal edges of mandibular central incisors, and the standard deviation values (SD) in 50 subjects.

The minimum distance was 7.23 mm; the maximum distance was 15.17mm and mean distance was 10.9747 mm with standard deviation of 1.6995.

### Table II:

Shows the minimum, maximum and mean distance between anterior attachment of lingual frenum and incisal edges of mandibular central incisors and the standard deviation value in single band, triple bands and multiple bands of frenal attachments.

- a. In single band seen in 19 subjects; minimum distance was 7.41 mm, maximum distance was 15.17mm, mean distance was 10.9061 mm with standard deviation of 1.814.
- b. In triple bands seen in 25 subjects, minimum distance was 7.23 mm, maximum distance was 13.20 mm; mean distance was 10.7864 mm with standard deviation of 1.6398.
- c. In multiple bands seen in 6 subjects, minimum distance was 9.33 mm; maximum distance was 13.75mm and mean distance was 13.75mm with standard deviation of 1.4636.

**Table III**

Shows the statistical comparison among 50 subjects and single, triple and multiple bands of lingual frenum.

- a. In analysis of variation (ANOVA) test done on the mean distance of 50 subjects, the F ratio was 1.233. On taking reference of this value with table value, the probability 'P' was 0.304. The "P" value was more than 0.05 which indicated that mean distances between 50 subjects were statistically not significant..
- b. In DUNNETT test done among the mean distance of single, triple and multiple bands, mean difference between single and triple band was 0.1197 (p value 0.817); mean difference between single and multiple band value was -1.0705 (p value 0.183) mean difference between triple band and multiple band is -1.1903 (p value 0.128). The p value in all cases were more than 0.05 which indicated that considering one band as control and comparing all other band against it these were statistically insignificant.

**Table IV**

Shows the mean distance, standard deviation and

student unpaired "t" test value in male and female subjects with single, triple and multiple bands of lingual frenum.

As the sample size of male and female with multiple bands was small (n = 6); no statistical data could be obtained so it was included with the sample of triple bands.

- a. Mean distance in male with single band (n = 11) was 11.5761 mm(SD 1.9254) ; female with single band (n=8) was 9.9850mm (SD 1.2238) and 'p' valve was 0.056.
- b. Mean distance in male with triple bands (n=14) was 11.7193 mm (SD 1.2343); female with triple bands (n=17) was 10.8382mm (SD 1.7622) and 'p' valve was 0.054.

The 'p' valve in all the cases were more than 0.05 which was non significance. Hence, the number of bands in male and female did not influence the distance between anterior attachment of lingual frenum and incisal edges of mandibular central incisor.

**Table V**

Shows the pattern of lingual frenum in 500 dentulous and 100 edentulous subjects.

- a. In dentulous subjects; 147 subjects (male 76, female 80) had single band (29.4%); 280 subjects (male 176, female 104) had triple bands(56%) and 73subjects (male 50; female 23) had multiple bands (14.6) of lingual fernum.
- b. In edentulous subjects, 38 subjects (male 14; female 24) has single band (38% ), 45 subjects (male 25; female 20) had triple bands (45%) and 17 subjects (male 10; female 7) had multiple bands (17%).

**Table I**

MEAN DISTANCE BETWEEN ANTERIOR ATTACHMENT OF LINGUAL FRENUM AND INCISAL EDGES OF MANDIBULAR CENTRAL INCISORS AND THE STANDARD DEVIATION VALUES (SD) IN 50 SUBJECTS.

| No. of Subjects | Minimum Distance | Maximum Distance | Mean Distance | Standard Deviation |
|-----------------|------------------|------------------|---------------|--------------------|
| 50              | 7.23 mm          | 15.17mm          | 10.9747mm     | 1.6995             |

**Table II**

MEAN DISTANCE BETWEEN ANTERIOR ATTACHMENT OF LINGUAL FRENUM AND INCISAL EDGES OF MANDIBULAR CENTRAL INCISORS AND THE STANDARD DEVIATION VALUE IN SINGLE BAND, TRIPLE BANDS AND MULTIPLE BANDS OF FRENAL ATTACHMENTS.

| Types of lingual frenum | No. of Subjects | Minimum Distance | Maximum Distance | Mean Distance | Standard Deviation |
|-------------------------|-----------------|------------------|------------------|---------------|--------------------|
| Single band             | 19              | 7.41mm           | 15.17mm          | 10.9061mm     | 1.8147             |
| Triple bands            | 25              | 7.23mm           | 13.20mm          | 10.7864mm     | 1.6998             |
| Multiple bands          | 6               | 9.33mm           | 13.75mm          | 11.9767mm     | 1.4636             |

**Table III**

STATISTICAL COMPARISON AMONG 50 SUBJECTS AND SINGLE, TRIPLE AND MULTIPLE BANDS OF LINGUAL FRENUM ANALYSIS OF VARIATION (ANOVA) - comparison among 50 subjects

| Number of subjects | F     | P     |
|--------------------|-------|-------|
| 50                 | 1.223 | 0.304 |

#### DUNNETT Test among 3 bands of Lingual frenum

| (I) Band | (J) Band | Mean Difference (I-J) | "p"   |
|----------|----------|-----------------------|-------|
| single   | triple   | 0.1197                | 0.817 |
| single   | multiple | -1.0705               | 0.183 |
| triple   | multiple | -1.1903               | 0.128 |

$P > 0.05$  Not significant

**Table IV**

MEAN DISTANCE, STANDARD DEVIATION AND STUDENT UNPAIRED "T" TEST VALUE IN MALE AND FEMALE SUBJECTS WITH SINGLE, TRIPLE AND MULTIPLE BANDS OF LINGUAL FRENUM.

| Bands  | Sex    | N  | Mean Distance | Standard deviation | "t" value |
|--------|--------|----|---------------|--------------------|-----------|
| Single | Male   | 11 | 11.5761mm     | 1.9254             | 2.0470    |
|        | Female | 8  | 9.9850mm      | 1.2238             |           |
| Triple | Male   | 14 | 11.7193mm     | 1.2346             | 2.0293    |
|        | Female | 17 | 10.8382mm     | 1.7622             |           |

**Table V**

PATTERN OF LINGUAL FRENUM IN 500 DENTULOUS AND 100 EDENTULOUS SUBJECTS.

| Types of bands | Dentulous<br>n = 500       | Edentulous<br>n = 100    |
|----------------|----------------------------|--------------------------|
| Single band    | Male = 67<br>Female = 80   | Male = 14<br>Female = 24 |
|                | Total = 147 (29.4%)        | Total = 38 (38%)         |
| Triple bands   | Male = 176<br>Female = 104 | Male = 25<br>Female = 20 |
|                | Total = 280 (56%)          | Total = 45 (45%)         |
| Multiple bands | Male = 50<br>Female = 23   | Male = 10<br>Female = 7  |
|                | Total = 73 (14.6%)         | Total = 17 (17%)         |

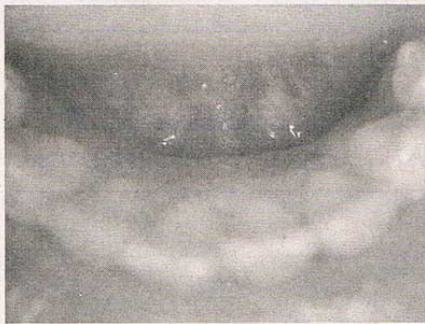

Photo 1: Lingual frenum with single band in dentulous state




Photo 4: Lingual frenum with triple band in edentulous state

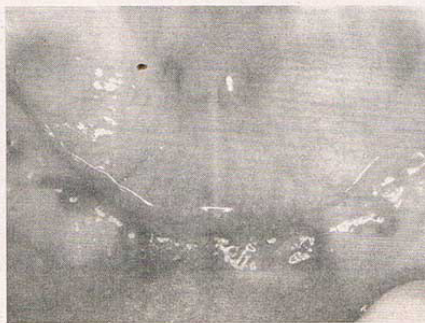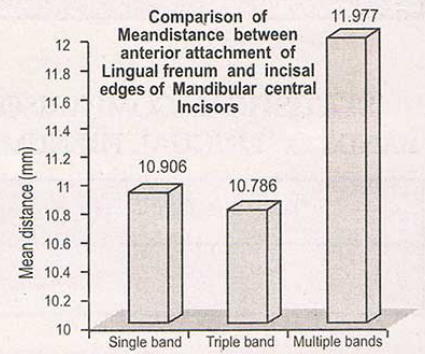


Photo 2: Lingual frenum with single band in edentulous state

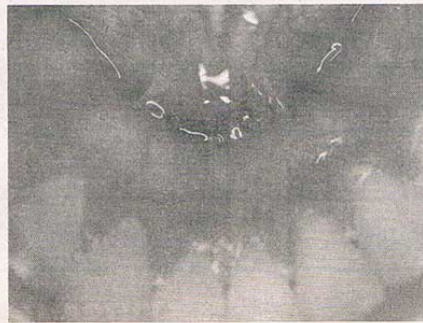


Photo 5: Lingual frenum with multiple band in dentulous state

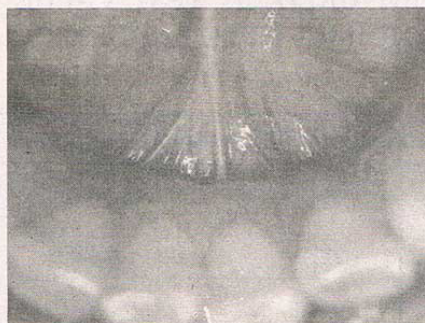
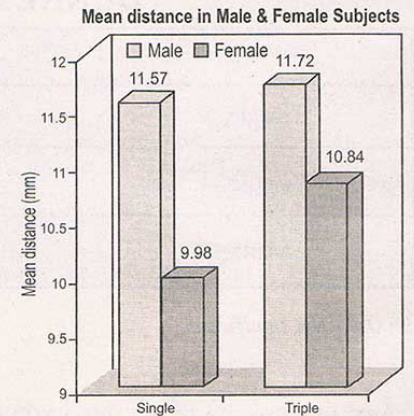
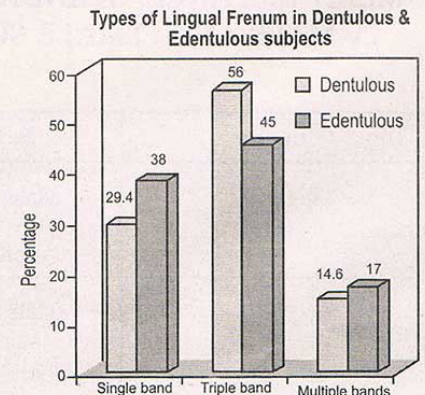


Photo 3: Lingual frenum with triple band in dentulous state



Photo 6: Lingual frenum with multiple band in edentulous state



## DISCUSSION

Achieving bio-mechanical, bio-esthetic and bio-phonetic position of artificial teeth is the prime objective of the Prosthodontist in replacement of the lost teeth. Pound<sup>19</sup> stated that to achieve a natural look, nature should be imitated by placing the artificial teeth in the same position as occupied by the natural teeth. Further, for a denture to be functionally, esthetically and phonetically pleasing, correct vertical dimension for occlusion should also be measured and established. Vertical dimension for occlusion and position of anterior teeth are initially established with maxillary and mandibular occlusal rims during jaw relation recording stage, and the final verification are made at try-in stage when the functional factors of phonetics and esthetics are individualized for each patient.

The facial structure of edentulous patient offer only indirect clues to these factors because definitive landmarks of reference are altered or lost following removal of all teeth. Finding the most suitable condition creates challenge during every complete denture fabrication and thus many professionals determine them through various means. However, there is no universally acceptable accurate method because of the variations in the physical characteristic of individuals.

The wider use of reliable pre-extraction records would be a great assistance in more accurately determining these factors and had been advocated for several years with many methods for its utilization<sup>3,7,9,11,23,25</sup>. Without previous records, the vertical position of the anterior teeth must be determined by the clinician's esthetic sense, relationship of the teeth to the ridges, measurements relative to the lip length and the use of phonetics<sup>2</sup>. All of these require much clinical judgement and experience before they can be used effectively.

On the basis of measurements from the mid-maxillary to mid-mandibular labial frenum,

McGrane<sup>16,9</sup> recommended that the distance from the incisal edge of maxillary and mandibular central incisors to the depth of the respective vestibular fold adjacent to the labial frenum are 22mm and 18mm respectively. Fayz<sup>9</sup> advocated use of 21.50 mm for maxillary central incisors and 16.5 mm for mandibular central incisors.

As compared to this labial frenum landmark, the lingual frenum is more significant due to its prominent location in midline lingual to the mandibular central incisors and its unaltered position after the extraction of lower anterior teeth. Woelfel<sup>27</sup> stated that lingual frenum attachment is 8.03 mm in average below the gingival sulcus of mandibular central incisors with range being 5.4 – 11mm. As the average crown height of mandibular central incisor is about 8 mm, so lingual frenum attaches about 12 – 19 mm below the incisal edges of these teeth. However, this structure has not been adequately exploited as a reference landmark.

Therefore, this study was undertaken to ascertain the anatomic pattern of lingual frenum of lower jaw and attempt to relate this structure to the incisal level of mandibular central incisors in dentate individuals so that the data thus obtained between them could be used to establish the incisal plane in mandibular central incisor during the arrangement of lower anterior teeth in complete denture prosthesis.

The result of this study showed that the mean distance between anterior attachment of lingual frenum and incisal edge of mandibular central incisors among 50 subjects was 10.9747mm. Bissasu<sup>3</sup> in his study on eighteen subject revealed that the mean distance between anterior attachment of lingual frenum and incisal edges of mandibular central incisors was 10.26mm, which is in close resemblance with the result of this study.

On statistical analysis, variation of sex and variation of anatomic form of single, triple and

multiple bands of lingual frenum show the trend of insignificance. In analysis of variation (ANOVA) test done on the mean distance of 50 subjects, the "P" value was 0.304 which indicated that these distance were statistically insignificant. In DUNNETTE "T" test, keeping one type band as control and compare other types of bands against it, the "P" value was 0.817 between single and triple bands, 0.183 between single and multiple bands, and 0.128 between triple and multiple bands. This means that the anterior attachments of lingual frenum, irrespective of sex and its anatomical variations has a constant relation to the level of incisal edges of mandibular central incisors in the vertical direction. The results on analysis thus revealed that the position of anterior attachment of lingual frenum could be considered as stable anatomical landmark.

This findings of the study would be useful as a guide in the initial determination of vertical dimension for occlusion at centric jaw relation record stage and later for the initial placement of anterior teeth in wax trial denture base. If the distance between anterior attachment of lingual frenum and incisal edge of mandibular central incisor is measured in the pre-extraction cast, this distance can be a guide to prepare the mandibular occlusal rim. The distance between the incisive papilla and incisal edges of maxillary central incisors on a pre-extraction cast is then used to orient the level of maxillary plane and this can be used to prepare the maxillary occlusal rim. Occlusal rims constructed to such requirements provide a good starting point for establishing the vertical dimension for occlusion and may not require much change, usually one or two millimeters, in either direction depending on the individual patient and the amount of tissue displacement cause by impression procedure. This pre-extraction values help to establish the tentative vertical dimension for occlusion reducing the clinical time.

This method thus will be a simple, reliable,

effective, practical and time saving means of reproducing the incisal level of mandibular central incisors in waxed up denture that existed prior to extraction of remaining teeth. This will encourage the practicing dentist to make pre-extraction records as a must in their general practice with pre-extraction study cast in complete denture construction for better bio-mechanical, bio-esthetics and bio-phonetic results.

## CONCLUSION

From the foregoing study the following conclusions are drawn:

The anatomical pattern of lingual frenum irrespective of dentulous or edentulous state consists of single band (33.7%), triple bands (50.5%) and multiple bands (15.8%)

The mean distance between anterior attachment of lingual frenum and incisal edges of mandibular central incisors is 10.9747mm.

Anatomic variation of lingual frenum and sex variation does not influence the reliability of measurement of vertical distance between lingual frenum and incisal edges of mandibular central incisors and are statistically insignificant.

The measurement of the distance between anterior attachment of lingual frenum and incisal edge of mandibular central incisors in pre-extraction diagnostic cast is reliable and can therefore be used as pre-extraction record to orient the vertical level of mandibular occlusal rim for tentative jaw relation recording stage.

The distance between anterior attachment of lingual frenum and incisal edge of mandibular central incisors is a reliable method to be used to co-relate the vertical position of mandibular central incisors during preliminary arrangement of lower anterior teeth for waxed trial up denture.

## BIBLIOGRAPHY

1. **Ballard:** Cardboard profile as pre-extraction record. *J Prosthet Dent* 1971; 25: 592-608.
2. **Bissasu M:** Copying maxillary anterior natural teeth position in complete denture. *J Prosthet Dent* 1992; 67:668-9.
3. **Bissasu M:** Use of lingual frenum in determining the original vertical position of mandibular anterior teeth. *J Prosthet Dent* 1999; 82: 177-81.
4. **Boos RH:** "Intermaxillary relation established by biting power. *J Am Dent Assoc* 1940; 27; 1192-9.
5. **Boyanov B.** Determining vertical dimensions of occlusion and centric relation. *J Prosthet Dent* 1970; 24: 18-24.
6. Dento-profile scale company, instruction Manual; 1938; Fond do Lac, Wis.
7. **Douglas JR, Maritato FR:** A roentgenographic method to determine the vertical dimension of occlusion for complete dentures. *J Prosthet Dent* 1967; 17; 450-5.
8. **Elliner CW:** Radiographic study of oral structures and their relation to anterior tooth position. *J Prosthet Dent* 1968; 19;36-45.
9. **Fayz F:** Use of anterior teeth measurement in determining occlusal vertical dimension. *J Prosthet Dent* 1987; 58: 317-322.
10. **Grave AMH:** Evaluation of incisive papilla as a guide to anterior tooth position". *J Prosthet Dent* 1987; 57; 712-714.
11. **Heintz WD:** Esthetic occlusal rims for providing jaw relations" *J Prosthet Dent* 1959; 9; 587-593.
12. **Hurst WW:** Vertical dimension and its correlation with lip length and inter occlusal distance. *J Am Dent Assoc* 1962; 64; 496-504.
13. **Kettlewell NL:** Factors concerning full denture *J Prosthet Dent* 1954;4: 30-34.
14. **Lytle RB:** Vertical relation of occlusion by the patient's neuromuscular perception. *J Prosthet Dent* 1964;14;12-21.
15. **Maritato FR:** A positive guide to anterior tooth placement *J Prosthet Dent* 1964: 14:848-853.
16. **McGrane HF:** Five basic principles of the McGrane full denture prosthesis *J Florida Dent Soc* 1949; 20:5-8.
17. **Merkeley H:** Completely standardized pre-extraction accord *J Prosthet Dent* 1953; 3, 657-659.
18. **Pleasure MA:** Correct vertical dimension and free way space. *J Am Dent Assoc* 1951; 43:160-163.
19. **Pound E:** Lost-fine arts in the Fallacy of the ridges. *J Prosthet Dent* 1954;4;6-16.
20. **Shanahan TE:** "Physiological vertical dimension and centric relation. *J Prosthet Dent* 1956; 6; 741-7.
21. **Silverman MM:** The speaking method in measuring vertical dimension. *J Prosthet Dent* 1953; 3; 193-199.
22. **Silver MM:** Occlusion in Prosthodontics and in the natural dentition. Mutual publishing company, 1962.
23. **Smith DE:** The reliability of pre-extraction records for complete dentures. *J Prosthet Dent* 1971; 25;592-608.
24. **Turrel AJW:** The pre-extraction recording of vertical dimension by intra oral method. *Dent Pract* 1955; 6:68-72.
25. **Turner LC:** Profile tracer, method of obtaining accurate pre-extraction records. *J Prosthet Dent* 1969; 21;364-70.
26. **Willis FM:** Features of the face involved in full denture prosthesis. *Dent Cosmos* 1935; 77;851-854.
27. **Woelfel JB:** Dental Anatomy and its relation to dentistry Pg. 76; Willimas and wilkins publication 5<sup>th</sup> edn 1999.
28. **Winkler S:** Essentials of complete denture prosthodontics. 2<sup>nd</sup> edn 135-141; Ishiyaku Euro American Inc. Publishers 1996.
29. **Wright WH:** Use of intra oral jaw relation wax records in complete dentures prosthesis. *J Am Dent Assoc* 1939; 26, 542-57.
30. **Zarb GA:** Bouchor's Prosthodontic treatment for edentulous patient. - 11<sup>th</sup> edn 210; 1988.