

# TRIGEMINAL NEURALGIA PRESENTING IN DENTAL CLINIC

## -A CASE REPORT

---

---

*Dr. Basant Pant*, PhD, Neurosurgeon  
Kathmandu Model Hospital  
Public Health Concern Trust (pfect-NEPAL)  
P.O.Box 6064, Kathmandu, Nepal

### Introduction

Trigeminal neuralgia or tic douloureux is characterized by brief episodes of extremely intense facial pain often radiating down the jaws. These episodes can occur spontaneously or can be triggered by light touch, chewing, or changes in temperature (i.e. cold). The pain is so intense as to be completely disabling. Trigeminal neuralgia is caused by irritation of the fifth cranial nerve (the trigeminal nerve) which is responsible for providing sensation to the face. This irritation is occasionally due to benign tumors or due to multiple sclerosis, either of which can usually be detected by a high quality MRI of the brain. In the majority of the cases, however, imaging of the brain does not reveal a cause of the nerve irritation. In such cases a small vessel (usually an artery but occasionally a vein) is often found to be compressing the root entry zone of the trigeminal nerve at the brainstem.

The first line of therapy is medical and consists of carbamazepine. Surgery is reserved for those who are unable to tolerate the side effects of these medications or for whom these medications are no longer effective.

Repositioning the vessel using microsurgery is an effective method of treating the people with this disorder.

Another category of surgical treatments are also effective in relieving trigeminal neuralgia. These involve making a partial lesion in the trigeminal nerve to produce facial numbness which is irreversible. The most commonly used version of this type of procedure is radiofrequency lesioning (RFL.) But these methods are inferior to more preferred microvascular decompression.

### Case summary

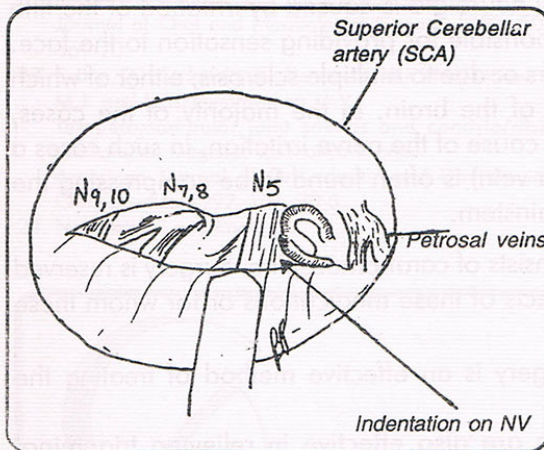
We present a case of a 70-years old female presented to our service in Kathmandu Model Hospital with 7 years history of severe lancinating pain in the facial region. It occurred every 1-2 hours in a severe bouts of pain lasting 30 second to one minute. Usually pain come in cluster of 3-4 episode. At times she was pain free for few months but had pain almost all the time. Pain was distributed in V2, V3 distribution of the trigeminal nerve. She repeatedly visited local dentist who thought the pain was originating from the tooth and subjected her for multiple tooth extractions. She was on carbamazepine 800 – 1000 mg/day for last 2 years, which was effective only in the initial period. There was no postural relation in the occurrence or severity of the pain.

On observation she had multiple severe bouts of facial pain lasting few seconds and in between she was completely pain free except for hyperesthesia lasting few minutes in the

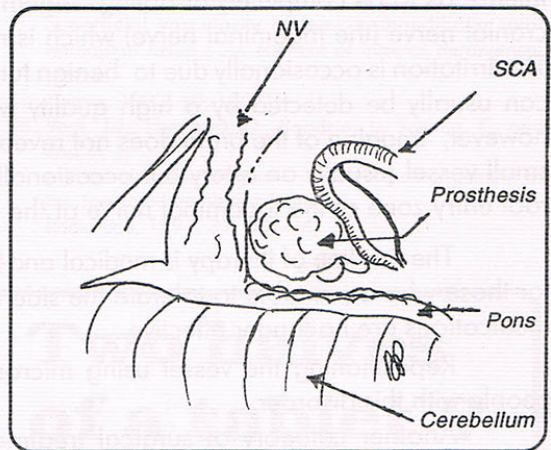
same distribution. Neurological examinations showed both motor and sensory function of trigeminal nerve intact. Her higher mental function, cranial nerve examination and rest of the neurological examinations were unremarkable.

With a clinical diagnosis of the trigeminal neuralgia, we sent the lady for cranial Magnetic Resonance Imaging study. There was no intracranial lesion in the vicinity of trigeminal nerve, and no clear-cut demonstration of the offending vessels could be detected.

We operated on the lady on Feb. 21, 1999 under general anesthesia. We made a small retrosigmoid craniectomy and proceeded further with operating microscope. Since the petrosal vein was small on that side we had no difficulty in reaching the trigeminal nerve and did not even sacrificed the petrosal vein. We could indentify a large tortuous superior cerebellar artery compressing on the trigeminal nerve. We dissected the artery from the root entry zone of the nerve and inserted Teflon felt in between the artery and the nerve. Once we were satisfied with the mobilization of the SCA the dura was sutured in watertight fashion and the wound closed without a drain.



*Fig. 1*  
Microscopic view of the trigeminal nerve and adjacent cranial nerves during the initial part of the surgery. A clear indentation of the nerve V by SCA was identified at the root entry zone.



*Fig. 2*  
Position of the SCA and nerve V at the end of the dissection. A Teflon felt was inserted inbetween to maintain the separation.

Postoperative course was uneventful, and the patient was completely symptom free postoperatively and had no further pain during the last 4 months follow-up. We believe this is the first successful microvascular decompression case reported in Nepal.

## Discussion

Microvascular Decompression (MVD) is an established form of treatment of the trigeminal neuralgia. Jenetta et al reported a success rate of more than 95%. Although it is associated with a small percentage of morbidity in the form of cerebro-spinal fluid leakage, infection or damage to the cranial nerve, this is relatively a straightforward procedure and the morbidity is quite low. The mortality rate of this surgery should be less than 1% and morbidity less than 10%. Although carbamazepine is the initial mode of therapy when ineffective, MVD is an option of therapy and should give a good result in experienced hand.

## Conclusion

We present a case of trigeminal neuralgia which was successfully treated with MVD. Since many patient with trigeminal neuralgia present to dental clinic it is important for the dental surgeons to understand the pathophysiology and surgical options of this disease.

## Reference

1. Barker FG 2<sup>nd</sup>, Jannetta PJ, Bissonette DJ, et al: The long-term outcome of microvascular decompression for trigeminal N Engl J Med, 334:1077-83 1996.
2. Barker FG 2<sup>nd</sup>, Janetta PJ, Bissonette DJ, et al: Trigeminal numbness and tic relief after microvascular decompression for typical trigeminal neuralgia, Neurosurgery, 40:39-45 1997.
3. Belber CJ, Rak RA: Balloon compression rhizolysis in the surgical management of trigeminal neuralgia, Neurosurgery 20:908-13, 1987.
4. Burchiel KJ, Clarke H, Haglund M, et al: Long term efficiency of microvascular dicompression in trigeminal neuralgia, J Neurosurgery 69:35-8, 1988.
5. Hakanson S: Trigeminal neuralgia treated by the injection of glycerole in to the trigeminal system. Neurosurgery 9:638-46, 1981.
6. Hardy DJ, Rhoton AL: Microsurgical relationship of the superior cerebellar artery and the trigeminal nerve. J Neurosurgery 49:669-46, 1978
7. Jannetta PJ: Microsurgical management of trigeminal neuralgia, Arch Neuro 142:800, 1985.
8. Meaney JF, Eldridge PR, Dunn LT, et al: Demonstration of neurovascular compression in trigeminal neuralgia with magnetic resonance imaging. Comparison with surgical findings in 52 consecutive operative cases. J Neurosurg, 83:799-805 1995.
9. Menzel J, Piotrowski W, Penzholz H: Long-term results of gasserian ganglion electrocoagulation. J Neurosurgery 42:140-3, 1975
10. Pamir MN, Zirth TA, Ozer AF, Kele, et al: Microvascular decompression in the surgical management of trigeminal neuralgia. Neurosurg Rev, 18:163-7 1995.
11. VanLoveren H, Tew JM, Keller JT, et al: A 10-year Experience in the treatment of tyrigeminal neuralgia. J Neurosurgery 57:757-64, 1982.

