

Non syndromic generalised macrodontia

Mainali A¹, Denny C², Sumanth KN³, Ongole R⁴

¹Department in Charge, Department of Oral Medicine and Radiology, Kantipur Dental College and Hospital, Basundhara, Kathmandu Nepal, ²Assistant Professor, Manipal College of Dental Sciences, Mangalore, ³Professor & HOD, Thaiy Mugambiga Dental College & Hospital, Chennai, ⁴Associate Professor and Department in Charge, Manipal College of Dental Sciences, Mangalore

Abstract

The purpose of this report is to present a case of non-syndromic generalized macrodontia. Macrodontia is the term used to describe teeth which are larger than normal. Three types of macrodontia are recognized: true generalized macrodontia, relative generalized macrodontia and macrodontia involving a single tooth. Literature review reveals that generalized macrodontia is usually associated with syndromes. Macrodontia may be associated with other syndromes; early recognition of this anomaly is essential to provide proper management. There are many cases reported with macrodontia associated with syndrome, however, our case is particularly unique as it had generalized macrodontia, and was not associated with any syndrome. Macrodontia may cause problems with aesthetics and also crowding if there is discrepancy between the dimensions of the teeth and size of the jaw treatment.

Key words: Macrodontia, True generalized, Associated with syndromes

Introduction

Variation in size, form and morphology of the teeth result in anomalies such as macrodontia, microdontia, hyperdontia, hypodontia, taurodontism and dens in dente. Macrodontia or megadontia refers to teeth that appear larger than the normal size. Some or all teeth may be affected. Macrodontia can be classified as three types: true generalized macrodontia, relative generalized macrodontia and macrodontia involving a single tooth¹.

- i) True generalized macrodontia - several teeth are larger than normal. Seen in pituitary gigantism and pineal hyperplasia with gigantism.
- ii) Relative generalized macrodontia - teeth are normal or slightly larger than normal in small jaws.
- iii) Macrodontia of single teeth - this is relatively uncommon. The tooth may appear normal in every aspect except for its size. True macrodontia of a single tooth should not be confused with fusion of teeth, in which, the union of 2 or more teeth results in a single large tooth, early in odontogenesis².

Case report

A 23 yr old female patient (Fig 1) visited Department of Oral Medicine and Radiology with a chief complaint of a

decayed lower left back tooth since 1 year. The tooth was asymptomatic. Her medical history and family history were unremarkable. Our patient was a full term baby and no genetic disorders were found in the family history. Results of physical examination and routine laboratory tests were within normal limits. She was moderately built and well nourished. Her vital signs were stable.

On extra-oral examination, no abnormalities were detected. General examination revealed no associated features like facial dysmorphism, abnormal hair implantation, Cutaneous syndactyly, webbed short neck, cryptorchidism and mental retardation.

On intra-oral examination, gingival bleeding was appreciated on probing. Dental caries was present with respect to 17,11,21,26,36,37,45,46,48 and 13 was buccally placed. Generalized macrodontia (Fig 2) was present along with Talon's cusp with respect to 11 and 21 (Fig 3). A working diagnosis of True Generalized macrodontia was given. However various syndromes are associated with generalized macrodontia, the features of which are summarized in Table 1.

Correspondence

Dr. Apeksha Mainali, MDS, Department in Charge, Department of Oral Medicine and Radiology, Kantipur Dental College and Hospital, Basundhara, Kathmandu Nepal



Fig 1: Extra oral picture of 25 yr old female patient

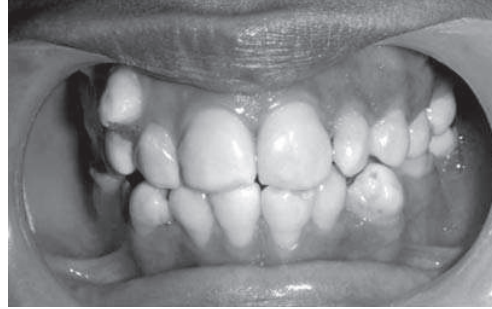

Fig 2: Generalized macrodontia of maxillary and mandibular teeth

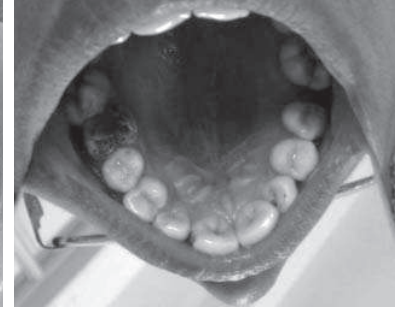

Fig 3: Generalized macrodontia of maxillary teeth- palatal view (Talon's cusps visible on 11 and 21)

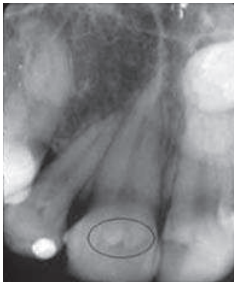

Fig 4 (a): Intra Oral Periapical Radiograph of 11, 21 showing teeth larger than normal

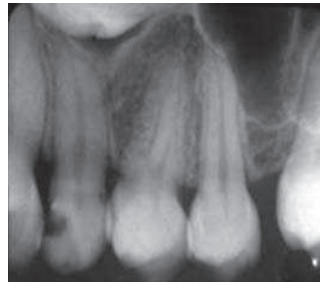

Fig 4 (b): Intra Oral Periapical Radiograph of 22,24,25 showing teeth larger than normal, also shows impacted 23

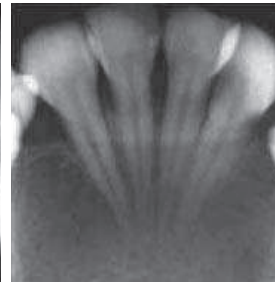


Fig 4 (c): Intra Oral Periapical Radiograph of 31,32,41,42 showing teeth larger than normal.

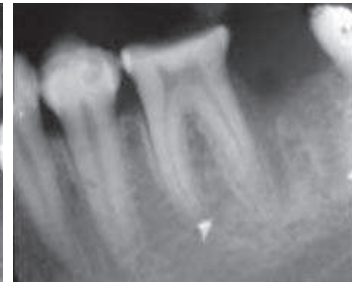


Fig 4 (d): Intra Oral Periapical Radiograph of 45, 46 showing teeth larger than normal.

Full mouth intra oral periapical radiograph was taken which showed teeth larger than normal (Fig 4). Radiographic measurement of the mesiodistal dimension of the various teeth are depicted in Table 2.

As of date, the term "large" is still controversial and subjective. Generalized macrodontia is rare and tooth width also varies between males and females. In our case, the width of the central incisors was 12mm, however literature reveals that the average width of central incisors is 8-8.5mm³. The patient's other teeth were also larger than normal.

Discussion

Macrodontia of single tooth is relatively uncommon. Isolated teeth displaying macrodontia can result from twinning abnormalities that originate during the proliferation phase of development. Hemangioma/ Lymphangioma can result in an increase in the size and advanced development of adjacent teeth.³ Fusion and gemination are the most common twinning abnormalities, and both demonstrate enlarged crowns. Males demonstrate a higher frequency of macrodontia and hyperdontia, while females have a greater prevalence of microdontia and hypodontia¹. The aetiology of macrodontia is unknown, but genetic and environmental causes have been proposed. Generalized

macrodontia has been associated with chromosomal anomalies like XYY males (Klinefelter syndrome) and endocrine disorders like pituitary gigantism and insulin-resistant diabetes. Localized macrodontia has been associated with syndromes like the otodontal syndrome especially in the posterior segment and patients with unilateral facial hyperplasia who exhibit macrodontia on the affected side⁴. In our case we found enlarged teeth in normal-size jaws, so it can be classified as true generalized macrodontia which was not associated with any syndrome. Radiographic features include an increased size in both erupted and unerupted teeth, the shape of the tooth is usually normal, but some teeth may show mildly distorted morphology³.

Generalized macrodontia may pose serious aesthetics and functional disturbances such as malocclusion, crowding and disfigurement. Orthodontic treatment can be accomplished if arch length discrepancy develops. Crown and bridge prosthodontic reconstruction may help to achieve an esthetic appearance. Orthodontic correction of the malocclusion was planned in our patient.

Though we report a case of True Generalised Macrodontia without syndromic association, practitioners should be aware of various syndromes that exhibit True

Generalised Macrodonia. Recognizing such syndromes early will help in planning appropriate dental and medical care to such patients.

Table 1: Syndromes Associated With Macrodonia

Syndromes	Clinical features
Otodental syndrome ^{5,6,7}	Autosomal dominant. Abnormalities of deciduous and permanent dentition included bulbous canines, globe-shaped posterior teeth and agenesis of maxillary premolars. High-frequency sensorineural hearing loss, generalized macrodonia, delayed mineralization of the mandibular premolars, and supplementary permanent maxillary canines.
Schinzel-Giedion syndrome ^{8,9,10}	The orofacial features include coarse facies, frontal bossing, ocular hypertelorism, anterior open bite and macrodonia.
Dubowitz syndrome ^{11,12,13}	Rare condition. Affected individual presents with dysmorphic facial features and manifests growth retardation. dental features include macrodonia, hypodontia, delayed eruption, and midline diastema.
Cockayne's syndrome ^{14,15}	Patients with this syndrome present failure to thrive, short stature, premature aging, neurological alterations, photosensitivity, delayed eruption of the primary teeth, congenitally absent of some permanent teeth, partial macrodonia, atrophy of the alveolar process and caries.
KBG syndrome ¹⁶	Rare condition characterised by a typical facial dysmorphism, macrodonia of the upper central incisors, skeletal (mainly costovertebral) anomalies and developmental delay, short stature, electroencephalogram (EEG) anomalies (with or without seizures) and abnormal hair implantation. Cutaneous syndactyly, webbed short neck, cryptorchidism, hearing loss, palatal defects, strabismus and congenital heart defects are less common findings.

Table 2: Radiographic measurement of the mesiodistal dimension of various teeth

Right and left	In the present Case	Average width
Maxillary Central Incisor	11.1mm	8 mm
Maxillary Premolar	9mm	7mm
MandibularCentral Incisor	6mm	5mm
MandibularLateral Incisor	6mm	4mm
Mandibular first molar	12 mm	10mm

References

1. Neville BW, Damm DD, Allen AM, Bouquot JE. Oral and Maxillofacial Pathology, WB Saunders Company: Philadelphia; 2007.
2. Shafer WG, Hine MK, Levy BM. A textbook of oral pathology. 4th edition, pp 40 Philadelphia: WB Saunders, 1983.
3. Stuart C. White, Michael J. Pharoah Stuart C. Oral Radiology-Principles and Interpretation, 5th edition, New Delhi: Mosby, 2004.
4. Kyriazidou A, Mason C, & Bloch-Zupan A. "Macrodonia of mandibular second premolars: review of the literature and report of a case" International Journal of Paediatric Dentistry 13 (Suppl. 1): 5-68.
5. Van Doorne L, Wackens G, De Maeseneer M, Deron P "Otodontal syndrome" Int J Oral Maxillofac Surg. 1998 Apr; 27(2):121-4.
6. Sedano H, Moreira LC, De Souza RA, Moleri AB. "Otodontal syndrome: A case report and genetic considerations" Oral Surg Oral Med Oral Pathol Oral Radiol Endod 2001; 92:312-7.
7. Bloch-Zupan A, Goodman JR, "Otodontal syndrome Otodontal syndrome" Orphanet Journal of Rare Diseases 2006, 1:5.
8. Cooke ME, Davidson LE, Livesey SL "Schinzel-Giedion syndrome: interesting facial and orodontal features, and dental management" Int J Paediatr Dent. 2002 Jan; 12(1):66-72.
9. Gazali L I al, Farndon P, Burn J, Flannery DB, Davison C, and Mueller R F, "The Schinzel-Giedion syndrome" J Med Genet. 1990 January; 27(1): 42-7.
10. Maclennan A C, Doyle D, and Simpson R M, "Neurosonography and pathology in the Schinzel-Giedion syndrome" J Med Genet. 1991 August; 28(8): 547-49.
11. Chan KM, King NM. "Dubowitz syndrome: report of a case with emphasis on the oral features". J Dent Child (Chic). 2005 Sep-Dec; 72(3):100-3.
12. Winter R M "Dubowitz syndrome" J Med Genet. 1986 February; 23(1): 11-3.
13. Tsukahara M, Opitz J. M. "Dubowitz syndrome : Review of 141 cases including 36 previously unreported patients" American journal of medical genetics, 1996, vol. 63, no 1, pp. 277-89 .

14. Arenas-Sordo Mde L, Hernández-Zamora E, Montoya-Pérez LA, Aldape-Barrios BC "Cockayne's syndrome: a case report. Literature review" *Med Oral Patol Oral Cir Bucal*. 2006 May 1;11(3):E236-8.
15. Spivak G, "The many faces of Cockayne syndrome" *Proc Natl Acad Sci USA*. 2004 October 26; 101(43): 15273-4.
16. Miyauchi-Hashimoto H, Akaeda T, Maihara T, Ikenaga M, Horio T "Cockayne syndrome without typical clinical manifestations including neurologic abnormalities" *J Am Acad Dermatol* 1998 Oct;39(4 Pt 1):565-70.
17. Brancati F, Sarkozy A, Dallapiccola B." KBG syndrome Orphanet" *J Rare Dis*. 2006 Dec 12;1:50.