

# SINGLE SITTING ECONOMIC AESTHETIC POST CORE FABRICATION

Hiremath S S\*, Singh S K\*\*, Singh R K\*\*\*\*, Joshi S\*\*\*, Dali M\*\*\*, Lamichhane R\*\*\*

\* MDS. Asst. Professor. Dept. of Pediatric Dentistry.

\*\* MDS. Asst. Professor. Dept. of Prosthodontics.

\*\*\*\* MDS. Professor and Head, Dept. of Prosthodontics.

\*\*\* Final Year BDS Students.

## ABSTRACT

Ready-made resin posts system use light transmitting post (LTP) to build composite in layers (layered adhesion technique) resulting in multiple composite interfaces. A new technique is demonstrated here, which eliminates the composite interfaces and hence a single unit resin post and core is obtained with better physical qualities and economy of cost and time.

**Key words:** resin post and core, composite resin, aesthetic resin post and core, post-endodontic restoration, custom fabricated post-core.

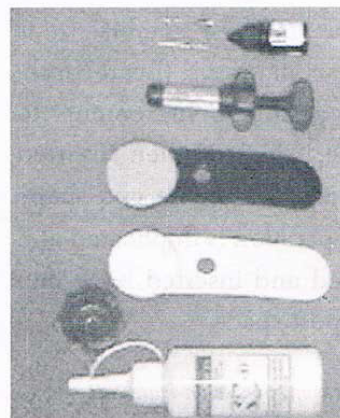## INTRODUCTION

Endodontically treated teeth have been traditionally restored with cast-metal posts prior to receiving aesthetic care<sup>1</sup>. The rationale for placing post is to enhance retention of the restorative core material to the remaining tooth structure and distribute stresses along the root uniformly<sup>2</sup>. After determining that post and core is required to retain core material, certain guidelines have to be followed prior to clinical procedures viz., post length, diameter, anatomic and structural limitations, type of post and core, type of restoration and core material, root selection in multirrooted tooth<sup>3</sup>.

Due to the difficulties associated with early posts, resources have been invested to develop biocompatible endodontic posts capable of satisfying functional and aesthetic criteria<sup>1, 3, 4, & 5</sup>. These initiatives have resulted in the introduction of carbon-based and glass-fiber posts (zirconium dioxide, carbon fibers, glass fibers, and light transmitting posts) with translucencies and moduli of elasticity closely approximating that of the dentin for use in adhesive dental procedures. These can either be cemented or bonded to the tooth structure<sup>5 & 6</sup>.

Ready-made resin posts system use light transmitting post (LTP) to build composite in layers (layered adhesion technique) resulting in multiple composite interfaces<sup>3 & 7</sup>. However a new technique is demonstrated here which eliminates the composite interfaces and hence a single unit resin post and core is obtained with better physical qualities. Unlike traditional post and core placement, which is multi-visit technique this is a single sitting procedure wherein custom-made resin post and core is fabricated in an easy, time saving and economical manner.

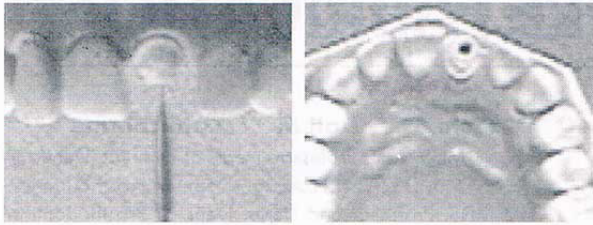
## MATERIALS AND METHODS



### Armamentarium:

Paeso reamer, reamer, resin bonding agent, composite resin, Elastomeric impression (silicon), Dappen dish and self cure acrylic resin.

**Step 1**

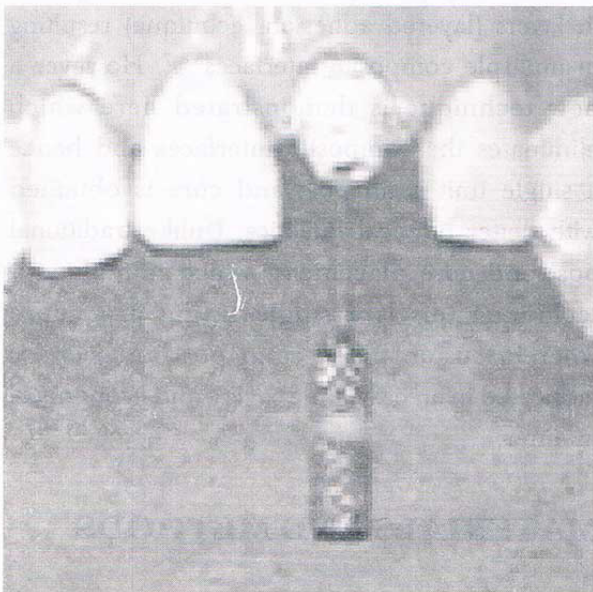


**Preparation of root canal space**

Perform thorough obturation of the root canal and prepare a post space leaving 1/3 of the apical space with Gates Glidden or Paeso reamer under rubber dam isolation. Confirmation of the apical seal and space preparation is done by radiograph.

**Step 2**

**Duplication of post space with acrylic resin**

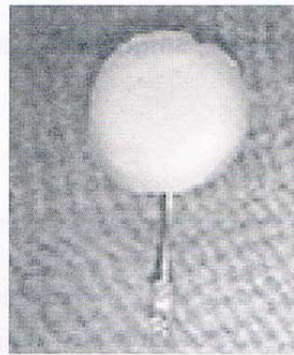

A solid metal sprue/reamer/file of suitable size is selected and self cure acrylic resin<sup>§</sup> (Bead-Brush/ Nealon technique) is added in increments to metal sprue/reamer/file, which is then inserted into post space preparation. The size and shape of entire post space preparation is duplicated and it is repeatedly removed and inserted back into the moist / lubricated post space.

<sup>§</sup> Alternatively inlay wax or resin impression materials can be used.

**Step 3**

**Elastomeric impression of the acrylic pattern**




Core is also fabricated at this point of time; after post space has been duplicated, self cure acrylic is added in layers to prepare the core. The post and core pattern is now removed and Elastomeric impression

is made using (silicon) Advantage: The cost and time of transportation, casting and lab procedures are eliminated.

**Step 4**

**Resin post and core in impression material before and after slicing**

The acrylic post core is removed and composite resin packed into mold space and carved. Additional curing is carried out after sectioning the impression material to ensure\* adequate polymerization of the composite resin. Slice the impression material with a sharp blade and do additional light curing.



\*There is a chance that adequate curing might not have been achieved in the apical area.


**Step 5**

**Rein post and core cemented in root canal space**

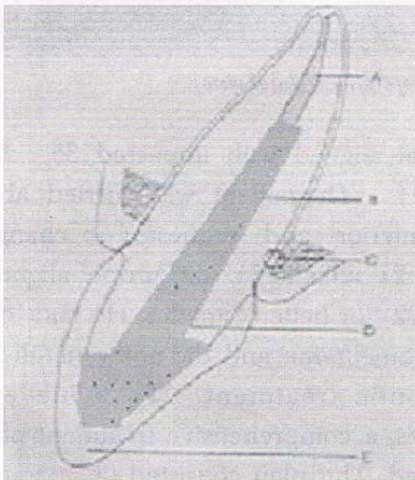
Clean the canals thoroughly to remove the lubricating agents/materials. Dry the canals with paper points. After the trial fit, self-etching primer/bonding agent (Prime & Bond NT or Clearfil SE) is applied in the canal space and cured according to manufacturers instructions.

**Step 6**

**diagrammatic representation of the Single sitting economic aesthetic post core fabrication:**



The custom-made composite resin post core is cemented using a dual cure resin luting cement. The built of core is now ready for final prosthetic preparation and fabrication (crown).



Diagrammatic representation of the Single sitting economic aesthetic post core fabrication.

- A: obturated apical root canal space
- B: resin post C: root D: resin post
- E: prosthetic jacket crown.

**CONCLUSION**

Post and core restorations with tooth colored material offer an improved aesthetic especially in anterior restorations. The technique described is easy, economical and cost effective and the single sitting composite resin post and core should prove their clinical applicability. This technique offers the advantage of being clinically well acceptable because it minimizes the time factor and utilizes the materials commonly available in a dental clinic setting.

**RE-PRINT REQUESTS**

E-mail: drsshiremath@indiatimes.com

**REFERENCES**

1. Martelli R: Fourth -generation intraradicular posts for the aesthetic restoration of anterior teeth. *Pract Periodontics Aesthet Dent.* 12(6): 579-84, 2000.
2. Berekally T: Contemporary perspectives on post-core systems. *Aust Endod J.* 29(3): 12-7, 2003.
3. Freedman GA: Esthetic post and core treatment. *DCNA,* 42(4): 799-812, 2001.
4. Velmurugan N, Parameswaran A: Custom-made resin post and core. *Operative Dentistry,* 29-1: 112-114, 2004.
5. Shetty A: aesthetic post core reconstructions. *Famdent practical dentistry handbook.* 4(2):50-53, 2003.
6. Vinayak V, Jain V: Aesthetic post and core-a case report and clinical considerations. *JIDA.* 73: 304-308, 2002.
7. Jindal J, Wadhvani KK: Endoesthetics-a new concept of endodontic rehabilitation. *JIDA.* 73: 88-92, 2002.