

Acute necrotizing ulcerative gingivitis: A case report in a pregnant patient

Shankar B TP¹, Sharma S², Ghale C³

¹Assistant Professor, ²HOD and Associate Professor, ³Dental Surgeon, Department of Periodontics, College of Dental Surgery, B.P.Koirala Institute of Health Sciences, Dharan, Nepal.

Abstract

Acute necrotizing ulcerative gingivitis is described as "a rapidly destructive, noncommunicable, gingival infection of complex etiology". It is characterized by necrosis of the crest of the gingival papillae, spontaneous bleeding, pain and halitosis. If it is left untreated, it may spread laterally and apically to involve the entire gingival complex, including the mucosa and alveolar bone, leading to necrotizing ulcerative periodontitis to necrotizing ulcerative stomatitis and finally noma. There are various predisposing factors like poor oral hygiene, food impaction, defective restorative margin, stress, smoking, hormonal imbalance, nutritional deficiencies etc. This case report describes the conservative management of ANUG and probable mechanism of pathogenesis of predisposing factors involved.

Key words: Acute necrotizing ulcerative gingivitis, Pregnancy

Introduction

Acute necrotizing ulcerative gingivitis (ANUG) has been reported widely and is common in developing countries¹. Classical diagnostic features include ulceration and necrosis of the interdental papillae, pain and spontaneous gingival bleeding. Additional features of the lesion that may be present are pseudomembrane and a characteristic 'fedor oris'. Malaise, fever and lymphadenopathy may be variably seen^{2, 3}. This entity used to be called "Trench Mouth" because of its prevalence in soldiers fighting in the trenches during World War I. It is caused by a combination of stress and poor oral hygiene, and is characterized by red, inflamed gingiva which is painful to the touch and bleeds easily. It also imparts a characteristic fetid odor to the breath.

ANUG is a rapidly destructive, noncommunicable, gingival infection of complex etiology. If it is left untreated, it may spread laterally and apically to involve the entire gingival complex, including the mucosa and alveolar bone, leading to necrotizing ulcerative periodontitis there by necrotizing stomatitis and noma. It is always necessary to diagnose the disease at an early stage and introduce prompt treatment to avoid further periodontal destruction and improve the quality of life of the patient.

Here we are presenting a case of ANUG in a pregnant patient.

Case Report

27 year old pregnant lady reported to the Periodontics OPD, College of Dental Surgery BPKIHS, Dharan, Nepal, with the chief complaints of gums pain, foul breath and deposits on the teeth since 3 days. Intraoral examination revealed soft deposit of pseudomembrane over the gingiva and the teeth. Areas of deposits were severely painful, and the breath odor was extremely unpleasant. The deposits were soft covering more than half of the crown of the teeth and adherent to attached gingiva (Fig 1). Multiple ulcers became apparent upon removal of the deposit. The ulcerated lesions were found more in interdental papilla and marginal gingiva. The ulcers were found to be more severe and painful in maxilla than in the mandible. The gingiva was tender on palpation. Pain was more of throbbing type aggravated on slight provocation and subsided after about 5-10 minutes. Similar ulcerated lesion was also found at the tip of the tongue which was in contact with lower lingual surface during resting position. (Fig 2)

Correspondence

Dr. Shankar Babu T.P., Assistant Professor, Department of Periodontics, College of Dental Surgery, B.P. Koirala Institute of Health Sciences, Dharan, Nepal, E-mail: dr_shankartp@rediffmail.com

On extra oral examination, there was no gross facial asymmetry detected, lips were competent, bilateral submandibular and submental group of lymph nodes were enlarged and tender on palpation and local rise in temperature was detected. Patient gave the history of elevated temperature and that she was taking antibiotics (amoxicillin 500mg) for the same since 4 days.

In the first visit after thorough examination, only conservative treatment like removal of local factors and maintenance of oral hygiene was planned. Removal of the necrotic slough was done by using small gauze pellets. Each pellet was used in small areas and slough was removed completely. This procedure was done in all the affected areas of the mouth and then the areas were irrigated with saline to remove the unattached debris. After the necrotic slough was removed, the ulcerated areas were exposed and some bleeding points were seen. Supragingival scaling was done with ultrasonic scaler as the patient was not having any kind of discomfort. She was instructed home care maintenance using a soft brush, hydrogen peroxide 3% mouth rinse 5 times a day and chlorhexidine 0.2% mouthwash twice daily. No antibiotic was prescribed as the patient was already taking amoxicillin 500mg orally. The Patient was recalled after 3 days for evaluation.

On the third day of the recall visit the patient was comfortable from pain, and the ulcers were showing signs of healing. No bleeding points were detected and the affected areas were non-tender. The ulcers were

still found in the interdental papilla and attached gingiva (Fig 3). Necrotic slough were still found mainly in the lingual aspect of lower anteriors. The tongue lesion also showed the signs of healing. Lymph nodes were palpable but non tender and the temperature was also normal.

The same procedure was repeated for cleaning the ulcerated sites of necrotic slough, and was irrigated with saline. She was instructed to continue the same home care procedure until the next visit which was planned after 4 days.

During examination of the oral cavity in the third visit the ulcers had reduced, and necrotic slough had decreased considerably. Lymph nodes were not palpable. There was only inflammatory enlargement seen. Complete scaling was done including subgingival areas to remove local deposits and to reduce the inflammatory enlargement. The patient was instructed to discontinue the hydrogen peroxide mouthrinse and continue the chlorhexidine mouthwash till the next visit. Subsequent appointment was scheduled after 15 days.

After 15 days, the ulcers had healed and necrotic slough was completely absent. Slight inflammatory enlargement was seen in the maxillary anterior labial and interdental papilla (Fig 4). There was a need for gingivoplasty to reduce the plaque retentive areas but was postponed until 6 months due to her pregnancy. Patient was advised to maintain oral health by regular dental visits and strict oral hygiene practice.

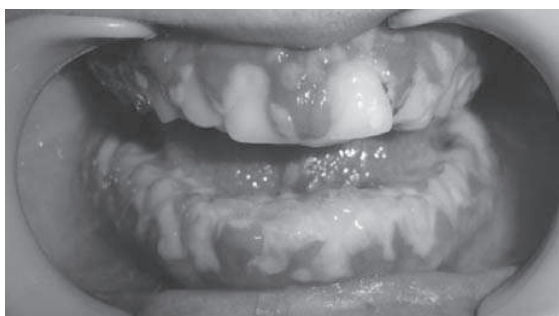

Fig 1: Necrotic slough covering interdental papilla and marginal gingiva

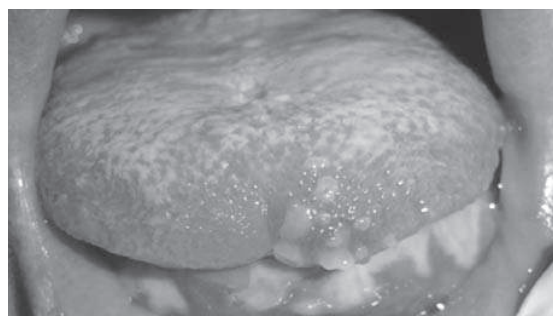


Fig 2: Ulcers on the tip of the tongue

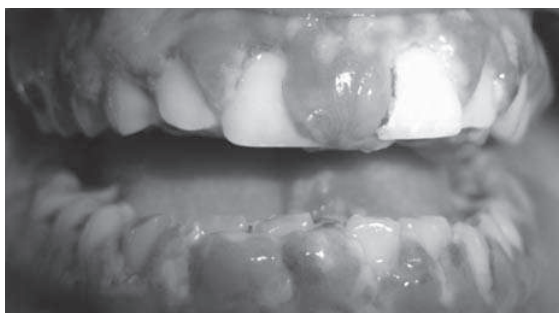


Fig 3: 2nd visit-Ulcers showing signs of healing and reduced necrotic slough

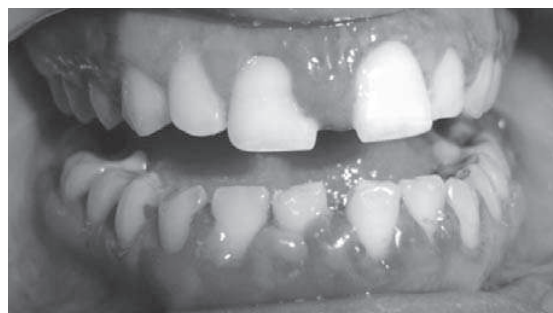

Fig 4: 4th visit-ulcers are healed, only inflammatory enlargement is seen

Discussion

ANUG is a rapidly destructive anaerobic infectious disease with toxic systemic manifestations. This disease entity was present as early as 400BC in Greek soldiers, but it was first described by Plaut in 1894 and Vincent in 1896. It is caused mainly by Fusiform bacilli and Spirochetes. Previously it was called as Vincent's disease and subsequently acquired long list of names like Trench gums, Acute ulcerous gingivitis, Vincent's gingivitis, Vincent's stomatitis, Plaut-Vincent's stomatitis, Fusospirochetal gingivitis, Fetid stomatitis, Gilmer's disease and Septic gingivitis to name a few. There has been a considerable confusion concerning the exact clinical pictures of this infection. The common clinical picture involves ulcers in the gingiva mainly occupying the interdental papilla and attached gingiva, punched out appearance due to ulcers in the interdental papilla and pseudomembranous slough covering these ulcers.

In the present case report we have discussed the complete case picture in initial and subsequent visits. The local debridement and vigorous oral hygiene practice with antibiotic coverage has healed the lesion considerably. Patient was relieved from pain, fetid odor and necrotic slough completely with this initial approach. This conservative mode of treatment can be a reliable method for treating ANUG especially in the pregnant patient. Plaque retentive shelf like areas of the marginal gingiva and interdental papilla, pseudopocket in the anterior maxilla were left untreated or corrected due to the pregnancy status as it was not affecting her routine quality of life. These treatments were postponed for 6 months after labor.

The main predisposing factors in our case were stress and pregnancy. Stress plays an important role in the progression and aggravation of various inflammatory diseases. Early reports have shown a positive correlation between acute necrotizing ulcerative gingivitis and psychological stress, suggesting psychosomatic effects on the periodontium, including endocrine dysfunction, lowered resistance to infection, and changes in diet, personal oral hygiene and parafunctional habits. Increased adrenocortical activity, which occurs in response to emotional stress, alters host immune responses^{5,6} and results in an inability to control the indigenous bacteria. During pregnancy the overall immunity of the person reduces and there is increased production of inflammatory cytokines and thus more prone to any kind of infection. In the oral cavity

during this phase, the plaque and calculus initiates the gingival and periodontal disease and transiently suppressed immune system aggravates the condition⁷. Numerous previous studies show the prevalence of preterm low birth weight babies (PLBW) in patients with sustained periodontal infection⁸. Stress along with pregnancy plays an important role in aggravation and progression of infectious gingival and periodontal diseases. In a microbiological analysis of ANUG along with fusospirochetes the second most common microorganism detected was *Prevotella intermedia*, a gram-negative anaerobic cocco-bacillus that forms black-pigmented colonies on blood agar supplemented with hemin and menadione⁹. This organism is frequently present in pregnancy gingivitis also. Thus further studies should be undertaken to determine the relationship between *P. intermedia* in ANUG and preterm low birth weight babies and thereby ANUG can be evaluated as potential risk factor for PLBW.

References

1. Enwonwu CO. "Epidemiological and biochemical studies of necrotizing ulcerative gingivitis and noma (cancrum oris) in Nigerian children." *Arch Oral Biol*; 1972;17:1357-1371.
2. Murayama Y, Kurihara H, Nagai et al 1994. "Acute necrotizing ulcerative gingivitis: risk factors involving host defense mechanisms." *Periodontol* 2000;6:116-124.
3. TM Arendorf, B Bredekamp, C-A Cloete, K Joshipura. "Seasonal variation of acute necrotising ulcerative gingivitis in South Africans". *Oral disease*; 2001;7:150-154.
4. Moulton R, Ewen S, Therman W. "Emotional factors in periodontal disease." *Oral Surg Oral Med Oral Pathol*; 1952;5:833-860.
5. Dennison DK, Smith B, Newland JR. "Immune responsiveness and ANUG." *J Dent Res*; 1985;64:197.
6. Johnson BD, Engel D. "Acute necrotizing ulcerative gingivitis: a review of diagnosis, etiology and treatment." *J Periodontol*; 1986;57:141-150.
7. Ronald S. Gibbs. "Relationship between infections and adverse pregnancy outcomes – An overview". *Ann Periodontol*; 2001;6:153-163.
8. Fouzia Tarannum and Mohammed Faizuddin. "Effect of periodontal therapy on pregnancy outcome in women affected by periodontitis". *J Periodontal* 2007;78:2095-2103.
9. Kornman KS, Loesche WJ. The subgingival microbial flora during pregnancy. *J Periodont Res* 1980;15:111-122.