

Oral pyogenic granuloma – a case report

Kafle S¹, Pradhan S²

¹ Resident, ² Professor, Periodontology and Oral Implantology Unit, Department of Dental Surgery National Academy of Medical Sciences, Bir Hospital, Kathmandu, Nepal.

ABSTRACT

Pyogenic granuloma is a fast growing reactive proliferation of endothelial cells commonly on the gingiva which arises in response to various stimuli such as a low-grade local irritations, traumatic injuries or hormonal factors. Pyogenic granuloma which often arises in 2nd or 3rd trimester of pregnancy possibly because of the vascular effects of female hormones is termed as "Pregnancy Tumor". Clinically oral pyogenic granuloma is a smooth or lobulated exophytic lesion manifesting as small, erythematous papules on a pedunculated or sometimes sessile base, which is usually hemorrhagic. The condition is frequently associated with periodontal pain and discomfort, in some cases interfering with mastication and creating esthetic problems.

Keywords: gingiva, hormonal factors ,pregnancy, pyogenic granuloma

INTRODUCTION

Pyogenic granuloma (also known as a "Granuloma gravidarum," and "Pregnancy tumor") is a common tumor-like growth of the oral cavity or skin that is considered to be non-neoplastic in nature. It was first reported in English literature by Hullahen's in 1844 and was first originally described in 1897 by two French surgeons, Poncet and Dor, who named this lesion otomyosis hominis but the term "Pyogenic granuloma" or "granuloma pyogenicum" was introduced by Hartzell in 1904. It was also called a Crocker and Hartzell's disease.¹ Angelopoulos (1971) histologically described it as "hemangiomas granuloma" due to the presence of numerous blood vessels and the inflammatory nature of the lesion. Cawson *et al* (1998) in dermatologic literature have described it as "granuloma telangiectaticum" due to the presence of numerous blood vessels seen in histological sections. They described two forms of pyogenic granulomas, the lobular capillary hemangioma (LCH) and the non-lobular capillary hemangioma (non-LCH). Pyogenic granulomas commonly occur on the skin or the

oral cavity but seldom in the gastrointestinal tract.

The name for pyogenic granuloma is misleading because it is not a true granuloma. In fact, no relationship exists between bacteria and emergence of this reactive proliferation. In actuality, it is a capillary hemangioma of lobular subtype which is the reason they are often quite prone to bleeding. It is a hyperactive benign inflammatory lesion commonly seen in the oral cavity with gingiva being the most common affected site followed by buccal mucosa, tongue and lips. Oral pyogenic granulomas show a predilection for the gingiva, accounting for 75% of the cases. It usually arises in response to various stimuli such as low-grade local irritations, traumatic injuries, hormonal factors, or certain kinds of drugs. Pyogenic granuloma may occur in all age groups, though it is predominantly seen in young females in the second decade of life because of the hormonal changes in this period.² Local irritants such as calculus, foreign material in the gingiva and poor oral hygiene are the precipitating factors. In this article, a case report of a pyogenic

Correspondence: **Dr. Shristi Kafle**; e-mail: shristi@gmail.com

Case Report

granuloma of the gingiva in a 24-year-old female patient who presented with a localized tumor like enlargement in the palatal aspect of upper left quadrant of the jaw is presented.

CASE REPORTS

A 24-year-old female visited to the Department of Dental Surgery, Periodontology and Oral Implantology Unit with a chief complain of a swelling in the upper left jaw region, which caused discomfort while eating. The patient reported that she noticed the swelling around 6 months back during her 2nd trimester of pregnancy, which was painless and gradually increased in size, during this period, she had visited nearby paramedical for a consultation. She had stopped brushing the area due to bleeding from the area since then.

On extraoral examination, there was no visible swelling on the left side of the maxilla. Intraoral examination revealed a large pedunculated lobulated gingival overgrowth extending on palatal surfaces of 22, 23 and 24. It was reddish pink in color with white patches and was approximately 16 mm × 24 mm in size. The surface was smooth with no ulcerations and it appeared ovoid in shape (Figure 1). Oral hygiene status was fair. Teeth associated with it did not show any mobility. Radiographically, there were no visible abnormalities and the alveolar bone in the region of the growth appeared normal (Figure 2). Routine hematological analyses was found to be normal. A provisional diagnosis of pyogenic granuloma was made. The differential diagnosis included peripheral ossifying fibroma, peripheral giant cell granuloma, hemangioma and fibroma.

The medical history of a patient was uneventful except being a lactating mother of one month baby and so the case was prepared for surgery on the basis of the clinical and radiographic evidence. Oral prophylaxis was completed and the lesion was excised under aseptic conditions. Excision of the lesion up to and including the mucoperiosteum was carried out under local anesthesia using a scalpel and blade, followed

by curettage and through scaling of the involved teeth. Periodontal dressing was placed and the patient was recalled after 1 week for removal of the pack and checkup. The excised tissue (Figure 3) was sent for histopathological examination.

Histopathological report revealed polypoid lesion lined by stratified squamous epithelium with focal area of ulceration. Subepithelium showed lobules of capillaries lined with endothelial lining. The underlying connective tissue stroma showed dilated and engorged blood vessels, extravasated red blood cells, angiogenesis, few inflammatory cells and bundles of collagen fibers. There was no any evidence of malignancy in the sections examined (Figure 4). The definite diagnosis of pyogenic granuloma and histologic diagnosis of lobular capillary hemangioma were made. The patient was recalled every 3rd month for maintenance and to check for possible recurrence. This case is being followed up for a period of 9 month and there has been no recurrence so far (Figure 5).

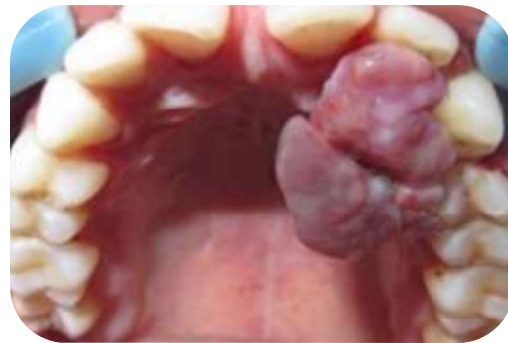


Fig 1: Pre-operative photograph of gingival over growth

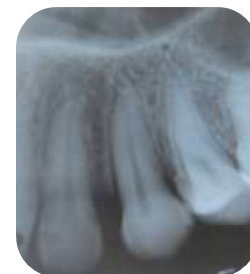

Fig 2: Intraoral Periapical radiograph

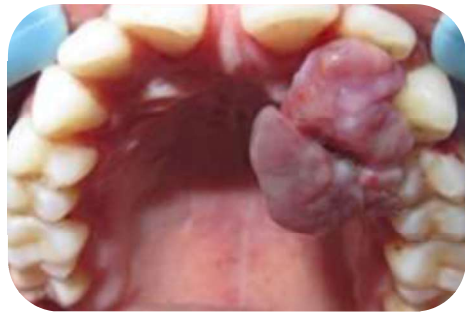

Fig 3: Excised tissue

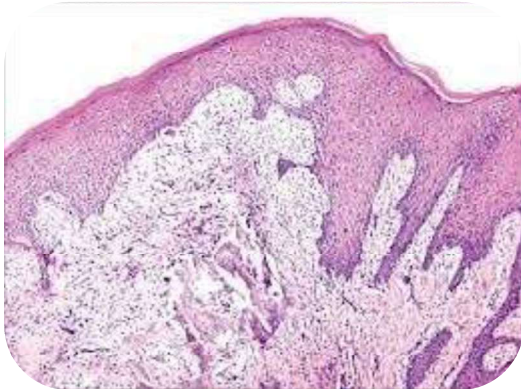


Fig 4: Histologic section of a gingival overgrowth

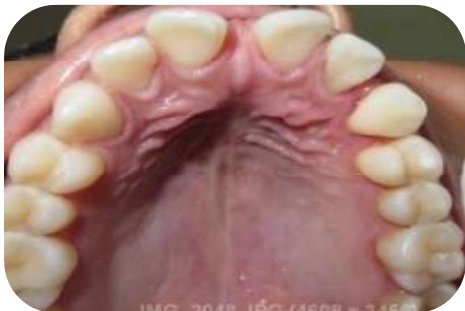

Fig 5: Post-operative photograph (9 month follow-up)

DISCUSSION

Regezi *et al.*³ suggested that pyogenic granuloma is caused by a known stimulant or injury such as calculus or foreign material within the gingival crevice resulting in exuberant proliferation of connective tissue. Ainamo (1971) suggested that routine tooth brushing habits cause repeated trauma to the gingiva resulting in irritation and formation of these lesions. Release of variety of endogenous substances and angiogenic factors caused disturbances in the vascularity of the affected area. Trauma to deciduous teeth, aberrant tooth

development, occlusal interferences, immunosuppressive drugs such as cyclosporine and wrong selection of healing cap for implants⁴ are some of the other precipitating factors for pyogenic granulomas.

Oral pyogenic granulomas occur in all age groups, children to older adult, but are more frequently encountered in females in their second decade due to the increased levels of circulating hormones estrogen and progesterone. Hosseini *et al.*⁵ observed that gingival enlargements increased in pregnancy and atrophied in menopause. Yuan *et al.* (2002) concluded that the morphogenetic factors were higher in pyogenic granuloma rather than normal gingiva supporting the mechanism of angiogenesis in oral pyogenic granulomas in pregnant females. Due to its frequent occurrence in pregnant females pyogenic granuloma is also called as granuloma gravidarum or pregnancy tumor. Hormonal changes and reaction of plaque bacteria are responsible for pregnancy gingivitis in some pregnant female patients. Jafarzadeh *et al.*⁶ has reviewed the correlation of oral pyogenic granuloma, pregnancy and the role of oral hormonal contraceptives in detail. However, the effects of female hormones on oral pyogenic granulomas was questioned by Bhaskar and Jacoway (1966) since they found lesions both in males and females with no specific sex predilection.

Bhaskar and Jacoway also demonstrated the presence of gram positive and gram negative bacilli in the superficial areas of the ulcerated form of pyogenic granuloma, rather than the non-ulcerated form suggesting that these organisms could be contaminants from the oral cavity. This probably justifies the inclusion of the term "pyogenic" in pyogenic granuloma. Oral pyogenic granuloma show prominent capillary growth within a granulomatous mass rather than the real pyogenic organisms and pus, so the term pyogenic granuloma is a misnomer and it is not a granuloma in the real sense.⁷

Case Report

Pyogenic granuloma of the oral cavity appears as an elevated, smooth or exophytic, sessile or pedunculated growth covered with red hemorrhagic and compressible erythematous papules, which appear lobulated and warty showing ulcerations and covered by yellow fibrinous membrane. The color varies from red, reddish purple to pink depending on the vascularity of the growth.⁸ The gingiva, especially the marginal gingiva is affected more than the alveolar part. Besides the gingiva it is also noticed on the lips, tongue or buccal mucosa, affecting the maxilla more than the mandible, the anterior region than the posterior with the buccal surfaces being affected more than the lingual surfaces. The size varies from a few millimeters to several centimeters and it is usually slow growing, asymptomatic, painless growth, but at times it grows rapidly.⁹

Histologically pyogenic granulomas are classified as the LCH type and the non-LCH type. The LCH type has proliferating blood vessels organized in lobular aggregates, no specific changes such as edema, capillary dilation or inflammatory granulation were noted. The non-LCH type consisted of a vascular core resembling granulation tissue with foci of fibrous tissue. The lobular area of the LCH type has a greater number of blood vessels with small luminal diameter than that in a non-LCH type of pyogenic granuloma. In the central area of the non-LCH pyogenic granuloma a greater number of vessels with perivascular mesenchymal cells non-reactive for alpha smooth muscle actin (SMA) is detected as compared with the lobular area of the LCH type pyogenic granuloma, thereby Epivatianos *et al.*, suggested that the LCH and the non-LCH pyogenic granulomas have different pathways of evolution.¹⁰ Sato *et al.* (2002) described most oral pyogenic granulomas as the LCH type histologically. They investigated the relationship of human endothelial receptor tyrosine kinase Tie2 and its expression in the lobular capillary hemorrhage LCH type pyogenic granulomas and that the expression of Tie2 in the ovoid cells with the presence of alpha SMA antibodies played an important role in the development

and progression of the LCH type of pyogenic granulomas. Regezi *et al.* (2003) demonstrated a strong activity of angiogenesis in oral pyogenic granulomas by demonstrating prominent capillary growth in the hyperplastic granulation tissue. Yuan *et al.*,¹¹ suggested the etiology of pyogenic granuloma to be due to an imbalance between the angiogenesis enhancers vascular endothelial growth factor (VEGF), basic fibroblast growth factor (bFGF) and angiogenesis inhibitors angiostatin and thrombospondin1. Vascular morphogenesis factors Tie-2, angiopoietin 2, ephrin B2 and ephrin were found to be up-regulated in oral pyogenic granulomas. Jafarzadeh *et al.*, (2006) emphasized the importance of decorin, VEGF, connective tissue growth factors, bFGF basic fibroblast growth factor on angiogenesis associated with profound inflammation. Sternberg *et al.*, (1999) described the natural course of the lesion in three phases of development as cellular phase, vascular phase and the phase of involution. Bhaskar and Jacoway (1966) described pyogenic granuloma as covered with parakeratotic or non-keratinized stratified squamous epithelium. Radiographic findings are usually absent.¹² However, Angelopoulos (1971) concluded that in some cases long standing gingival pyogenic granulomas caused localized alveolar bone resorption.

Differential diagnosis included peripheral giant cell granuloma, peripheral ossifying fibroma, metastatic cancer, hemangioma¹³, pregnancy tumor, conventional granulation tissue hyperplasia, Kaposi's sarcoma, bacillary angiomatosis and non-Hodgkins lymphoma. Due to the proliferating blood vessels differential diagnosis of pyogenic granuloma from a hemangioma is made histologically in which hemangioma shows endothelial cell proliferation without acute inflammatory cell infiltrate, which is a common finding in pyogenic granuloma. The diagnosis of pregnancy tumor is based on the history and the apparent influence of the female sex hormones. Excision and biopsy of the lesion is the recommended line of treatment unless it

Case Report

would produce a marked deformity and in such a case incisional biopsy is recommended. Conservative surgical excision of the lesion with removal of irritants such as plaque, calculus and foreign materials is recommended for small painless non-bleeding lesions. Excision of the gingival lesions up to the periosteum with thorough scaling and root planning of adjacent teeth to remove all visible sources of irritation is recommended.

Various other treatment modalities such as use of Nd: YAG laser, carbon dioxide laser, flash lamp pulse dye laser, cryosurgery, electrodesiccation, sodium tetradecyl sulfate sclerotherapy and use of intra lesional steroids¹⁴ have been used by various clinicians.

Treatment of oral pyogenic granulomas during pregnancy would depend on the individual case and ranges from preventive measures such as careful oral hygiene, removal of dental plaque and use of a soft toothbrush. Wang recommended control of bleeding by desiccation of bleeders, firm compression of the lesion, use of blood transfusions in a case of severe bleeding from a pregnancy tumor and in rare cases termination of pregnancy due to uncontrollable eclampsia have been documented (Wang *et. al*, 1997). In some cases shrinkage of the lesion after pregnancy may make surgical treatment unnecessary.¹⁵ In pregnant females recurrence of oral pyogenic granulomas is common so treatment should be preferably performed after parturition. However, if necessary, treatment can be completed in the second trimester with follow-up of the case post-parturition.

Recurrence of pyogenic granuloma after excision is a known complication but can be prevented. Recurrence rate for pyogenic granuloma is said to be 16 % of the treated lesions and so re-excision of such lesions might be necessary. Incomplete excision, failure to remove etiologic factors or repeated trauma contributes to recurrence of these lesions. Vilmann *et al.*,(1986) emphasized the need of follow-up, especially in pyogenic granuloma of the gingiva due to its much higher recurrence rate. The present case was followed up for a

period of 9 month and no recurrence was observed.

CONCLUSION

Pyogenic granuloma is a common lesion of the oral cavity, especially the gingiva which can be adequately treated with the correct diagnosis and proper treatment planning. A careful management of the lesion also helps in preventing the recurrence of this benign lesion.

REFERENCES

1. Hartzell MB. Granuloma pyogenicum. J Cutan Dis Syph 1904;22:520-5.
2. Sumanth Shivaswamy, Nazia Siddiqui, A. Sanjay Jain, Ajit Koshy, Sonal Tambwekar, Akhil Shankar. A rare case of generalized pyogenic granuloma: A case report. Quintessence Int 2011;42:493-499.
3. Regezi JA, Sciubba JJ, Jordan RC. Oral Pathology: Clinical Pathological Considerations. 4th ed. Philadelphia: WB Saunders; 2003. p. 115-6.
4. Dojcinovic I, Richter M, Lombardi T. Occurrence of a pyogenic granuloma in relation to a dental implant. J Oral Maxillofac Surg 2010;68:1874-6.
5. Hosseini FH, Tirgari F, Shaigan S. Immunohistochemical analysis of estrogen and progesterone receptor expression in gingival lesions. Iran J Public Health 2006;35:38-41.
6. Jafarzadeh H, Sanatkhan M, Mohtasham N. Oral pyogenic granuloma: A review. J Oral Sci 2006;48:167-75.
7. Regezi JA, Sciubba JJ, Jordan RC. Oral Pathology: Clinical Pathological Considerations. 4th ed. Philadelphia: WB Saunders; 2003. p. 115-6.
8. Mubeen K, Vijaylakshmi KR, Abhishek RP. Oral pyogenic granuloma with mandible involvement: An unusual presentation. J Dent Oral Hyg 2011;3:6-9.
9. Parisi E, Glick PH, Glick M. Recurrent intraoral pyogenic granuloma with satellitosis treated with corticosteroids. Oral Dis 2006;12:70-2.
10. Epivatianos A, Antoniadis D, Zaraboukas T, Zairi E, Pouloupoulos A, Kiziridou A, et al. Pyogenic granuloma of the oral cavity:

Case Report

- Comparative study of its clinicopathological and immunohistochemical features. *Pathol Int* 2005;55:391-7.
11. Yuan K, Jin YT, Lin MT. Expression of Tie-2, angiopoietin-1, angiopoietin-2, ephrinB2 and EphB4 in pyogenic granuloma of human gingiva implicates their roles in inflammatory angiogenesis. *J Periodontal Res* 2000;35:165-71.
 12. Kamal R, Dahiya P, Puri A. Oral pyogenic granuloma: Various concepts of etiopathogenesis. *J Oral Maxillofac Pathol* 2012;16:79-82.
 13. Eversole LR. *Clinical Outline of Oral Pathology: Diagnosis and Treatment*. 3rd ed. Hamilton: BC Decker; 2002. p. 113-4.
 14. Parisi E, Glick PH, Glick M. Recurrent intraoral pyogenic granuloma with satellitosis treated with corticosteroids. *Oral Dis* 2006;12:70-2.
 15. Bouquot JE, Nikai H. Lesions of the oral cavity. In: Gnepp DR, editor. *Diagnostic Surgical Pathology of Head and Neck*. Philadelphia: WB Saunders; 2001. p. 141-233.