

Positioning and Technical Errors in Orthopantomogram of Edentulous, Dentulous and Child Patient

Pandey S¹, Pai M K², Dhakal A³, Shrestha B⁴

¹Associate Professor, Department of Oral Medicine and Radiology

²Assistant Professor, Dean & Head, Department of Oral Medicine and Radiology

³Assistant Professor, Department of Clinical Anatomy

⁴Assistant Professor, Department of Oral Pathology

^{1,3,4}Chitwan Medical College, Tribhuvan University, Nepal

² College of Dental Sciences, Manipal University

ABSTRACT

Orthopantomogram is one of the routinely used investigations in dentistry. Therefore it is very important to be aware of the common errors of radiographs for proper radiographic diagnosis. Radiographs of all patient (n=1010) taken for a 3 months period in Oral Radiology Department of Manipal college of dental sciences were classified in four different groups, dentulous, edentulous partially edentulous and child patient. The radiographs are further evaluated for errors and found that tongue not resting against the palate, dark and light radiographs, radiopaque ghost shadow of the cervical spine superimposed on the symphyseal region and patient movement were found common errors. Fewer errors are likely to be made when a quality assurance regimen and proper training, which includes the recognition and correction of errors, are followed.

Keywords: Panoramic radiograph, Positional error, Technical error

INTRODUCTION

Panoramic radiographs have long been one of the most common means for imaging dental structures among dentists due to their many advantages.¹ Since the introduction of panoramic radiography into general practice of dentistry in the early 1960's, it has gained considerable popularity as a diagnostic tool. The panoramic film is used alone or in combination with other radiographic views. The simplicity of operation, the broader scope of examination, ability to project anatomic structures and their intervening parts, as well as the low radiation dose are reasons for its continuously growing popularity. The equipment available for panoramic radiography

has had rapid development during the last two decades. A variety of machines using different principles of x-ray beam rotation are available for the dental profession.² The value of panoramic radiograph is reduced when they are of poor diagnostic quality. This poor quality usually is not a result of an inherent limitation with the equipment but rather is a result of errors made by the operators during patient positioning and processing.²

Therefore, the aim of the study is to identify the most common positioning and technical errors among different patient group edentulous, partial edentulous, dentulous and child patients.

Correspondence: Dr. Sushma Pandey; e-mail: pandeyusma@gmail.com

MATERIALS & METHODS

This study was conducted in Department of Oral Medicine and Radiology, MCODS, Manipal over a period of 3 months between November 2009 and January 2010. Institutional Ethics Committee approval was taken from Kasturba Hospital, Manipal. Informed consent was taken from all the patients.

Methods

Panoramic radiographs of all the patients, who were taking radiographs for their own diagnostic purpose, were examined. Patient were positioned and OPG were taken by radiology technicians or post graduate students or faculty members on planmeca 2002cc panoramic machines. Then they were processed in promax processor and viewed under identical condition using a standard 15×30 light box in a room with subdued lighting. Radiographs were reported by the same person who has taken the radiograph to identify following panoramic errors as described by Langland.²

Technical Errors

1. Low density radiograph:
2. High density and completely black image
3. Fogged Radiograph:
4. When the cassette is placed backward.
5. Only portion of film exposed
6. Vertical white line in Radiograph:
7. Alternating white and black vertical lines
8. Random Artifacts
9. Processing problems
 - a. Streaking or uneven surface density
 - b. Static electricity
 - c. Smudge static marking
 - d. Glove smudge marking
 - e. Folding mark
10. Fingerprints and Fluoride artifacts:
 - a. Dark grey fingerprints: film contaminated by the developer
 - b. White fingerprints: fixer contamination
 - c. Stannous fluoride: black fingerprint mark
11. Crimp Marks

Positioning Error

12. If head is positioned too far forward:
13. If head is positioned too far back and teeth not biting the groove
14. Midsagittal plane positioning errors
 - a. Tilted head.
 - b. Off centered
 - c. Twisted or any combination
15. Occlusal plane positioning error:
 - a. Downward overangulation of head
 - b. Upward overangulation of head
16. Chin not rest on the chin support
17. Bite guide not used
18. Tongue not rest against palate
19. Lips open:
20. Prosthesis left in place
21. Eyeglasses artifact
22. Neck chain artifact
23. Ear jewelry artifact
24. Nose ring artifact
25. Leaded apron
26. Spinal column positioning error
27. Patient shoulders touching the cassette holder during movement
28. Distortion due to patient movement
29. Double Exposure

Panoramic radiograph were categorized as

- a. Edentulous
- b. Partially Edentulous
- c. Dentulous
- d. Child

Data were statistically analysed using SPSS version 16 for the most commonly occurring positional and technical error with respect to different dental state i.e edentulous, dentulous and child patient. Certain patients who have physical differences that preclude their being positioned properly at panoramic machine were excluded from the study.

RESULT

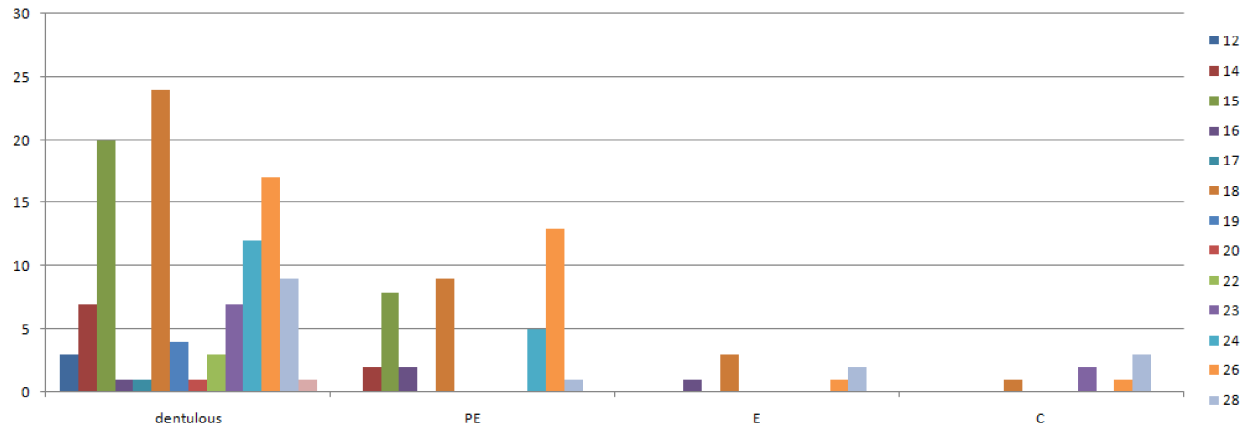
This study was conducted in Department of Oral Medicine and Radiology, MCODS, Manipal. 1010 panoramic radiographs taken in three month period were evaluated.

As shown in Table 1 and Graph 1, most common positional error in dentulous and edentulous group was palatoglossal air space shadow i.e n=24, n=3 respectively. In partial edentulous group, the most common positional error found was a radiopaque ghost shadow of the cervical spine superimposed on the symphyseal region (n=13). Whereas in pediatric

group, movement of the patient was the most common positional error (n=3)

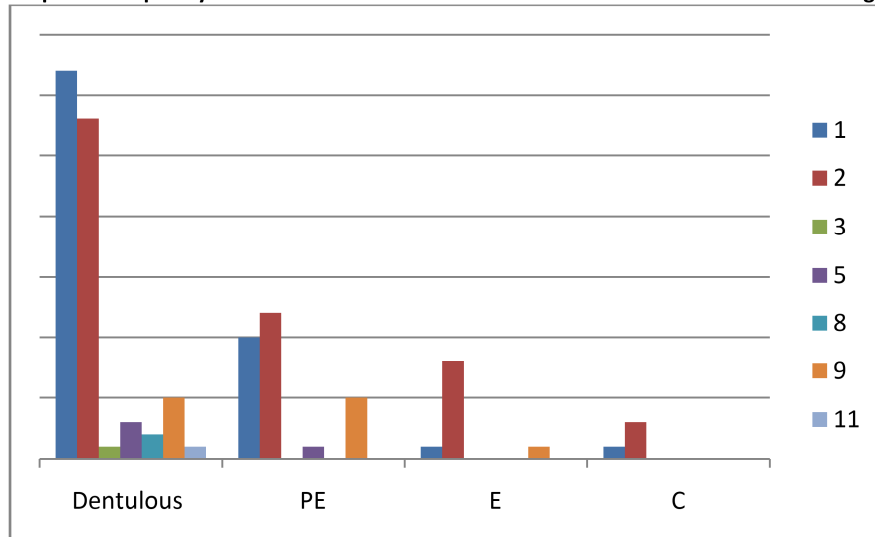
Table 2 and Graph 2 show, most common technical error in partial edentulous, edentulous and pediatric group was dark radiograph i.e n=12, n=8 and n=3 respectively, whereas in dentulous group it was light radiograph (n=32).

Graph 1 : Frequency of different positional errors taken in different dental state groups



12=If head is positioned too far forward, 14=Midsagittal plane positioning errors, 15=Occlusal plane positioning error, 16= Chin not rest on the chin support, 17=Bite guide not used , 18=Tongue not rest against palate, 19=Lips open, 20=Prosthesis left in place, 22=Neck chain artefact, 23=Ear jewellery artefact, 22=Neck chain artefact, 24=Nose ring artefact, 26=Spinal column positioning error, 28=Distortion due to patient movement, 29=Double Exposure
 D=Dentulous PE=partial edentulous state E= edentulous state c=child patient

Graph 2: frequency of some common Technical errors taken in Different dental state groups



1=low density radiograph/Light radiograph, 2=High density radiograph/Dark radiograph, 3=Fogged Radiograph, 5=Only portion of film exposed, 8=Random Artefacts, 9=Processing problems, 11=Crimp Marks
 D=Dentulous PE=partial edentulous state E= edentulous state c=child patient

Table 1: Frequency of different types of positional errors in different dental state group

Types of error	12	14	15	16	17	18	19	20	22	23	24	26	28	29	Total
Dental state															
D	3	7	20	1	1	24	4	1	3	7	12	17	9	1	110
PD	0	2	8	2	0	9	0	0	0	0	5	13	1	0	40
E	0	0	0	1	0	3	0	0	0	0	0	1	2	0	7
C	0	0	0	0	0	1	0	0	0	2	0	1	3	0	7
Total	3	9	28	4	1	37	4	1	3	9	17	32	15	1	164

12=If head is positioned too far forward, 14=Midsagittal plane positioning errors, 15=Occlusal plane positioning error, 16= Chin not rest on the chin support, 17=Bite guide not used , 18=Tongue not rest against palate, 19=Lips open, 20=Prosthesis left in place, 22=Neck chain artefact, 23=Ear jewellery artefact, 22=Neck chain artefact, 24=Nose ring artefact, 26=Spinal column positioning error, 28=.Distortion due to patient movement, 29=Double Exposure.
PE=partial edentulous stated, E=edentulous state, C-Chid (paediatric age group)

Table 2: Frequency of different technical errors taken in different dental state groups

		1	2	3	5	8	9	11	Total
Dstate	D	32	28	1	3	2	5	1	72
	PE	10	12	0	1	0	5	0	28
	E	1	8	0	0	0	1	0	10
	C	1	3	0	0	0	0	0	4
Total		44	51	1	4	2	11	1	114

1=low density radiograph/Light radiograph, 2=High density radiograph/Dark radiograph, 3=Fogged Radiograph, 5=Only portion of film exposed, 8=Random Artefacts, 9=Processing problems, 11=Crimp Marks
Dstate=dental state, PE=partial edentulous stated, E=edentulous state, C-Chid (paediatric age group)

DISCUSSION

In our study various errors were observed on 1010 panoramic radiographs examined. We have further evaluated the errors with respect to different patient groups, like edentulous, dentulous and child patient.

Among different dental state groups, light radiograph was common in dentulous patient whereas dark radiograph was common in partial edentulous, complete edentulous and pediatric group. In most of the case failure to equipment set up according to patient need was the common cause for this error. Similarly, among different positional errors, tongue not resting in the palate was common in dentulous and edentulous patient as well. This finding was in agreement with the study done by Glass et al³ who also found that the palatoglossal shadow was the most common error among edentulous patient. In partial edentulous group the spinal column positioning error was common findings. It can be explained by the fact that there is an inherent tendency for patients when holding the hands of the machine to slump. Therefore the operators need to make sure before taking the radiograph that the patient's back and spine

are erect with the neck extended. Among pediatric group most common positional error was patient movement. No study appears to have been carried out for pediatric group so far⁴ in spite of the fact that it is more important as the concerns over the radiation protection are greater in young. Experience suggests that children may find it difficult in positioning and easily get scared and moved when machine starts rotating. Another explanation is that most of the young patient could not follow the operators instructions.

CONCLUSION

The value of any diagnostic procedure depends upon the amount of information gained by its utilization⁵. In panoramic radiography, there are numerous factors which can reduce the diagnostic quality of radiographs. The quality of panoramic radiography could be improved by careful attention to radiographic technique and processing⁶. The results of our study indicate that the patient's not keeping the tongue raised during the exposure and film density errors were seen most often. Although a lower percentage of

errors were noticed when the radiographs were made by our operator groups, the study emphasizes both the importance of proper training to instruct the patient as well as the need to monitor equipment parameters considering the frequency of errors and repeats regularly occurring in particular dental state group.

REFERENCE

1. Peretz B, et al : *Common Errors in Digital Panoramic Radiographs of Patients with Mixed Dentition and Patients with Permanent Dentition* Int J Dent 2012, :584138.
2. Langland, O.E , Langlais R.P and Morris C.R. *Principles and practice of panoramic radiology.* Philadelphia, W.B. Saunders Co, 1982, pp84-156.
3. Glass BJ, Seals RR Jr, Williams EO. *Common errors in panoramic radiography of edentulous patients.* J Prosthodont 1994; 3:68-73
4. Natalia A. Brezden, B.S, Sharon L. Brooks, Ann Arbor, Mich. *Evaluation of panoramic dental radiographs taken in private practice.* ORAL SURG. ORAL MED. ORAL PATHOL. 1987;63:617-21
5. M Dhillon, et al. *Positioning errors and quality assessment in panoramic radiography* Imaging Science in Dentistry. 2012 December; 42(4)207
6. Rushton VE, Horner K, Worthington HV. *The quality of panoramic radiographs in a sample of general dental practices,* Br Dent J. 1999 Jun 26;186(12):630-3.