

Comprehensive complete denture rehabilitation, a way to achieve recovery of abused tissue: A case report

Bhusal DS¹, Joshi S², Shakya S³

¹Resident, ²Professor, Department of Prosthodontics, ³Dental Surgeon, Department of Dental Surgery, NAMS, Bir Hospital

Abstract

The prosthodontic treatment must provide for the edentulous patients bio-functional prosthetic restorations, bio-prophylactic for the surrounding tissues and esthetic harmony with the face and person as a whole. In this aim, an edentulous patient must be submitted to a methodical clinical examination in order to establish the quality of hard and soft tissues, which will indicate the degree of difficulty of the prosthetic treatment and modification in the treatment plan and to tailor the treatment according to individual needs. Additional investigation such as histology may be needed in case of pathological changes in hard or soft tissues within the oral cavity. The problem of managing abused tissues in a patient with morphologic abnormalities due to faulty prostheses is sometimes difficult to solve and need surgical intervention if the tissues fail to respond with the rest and conditioning material. Adequate healing time should be given for the operated area and modification in the treatment plan should be provided not to assault the tissue anymore.

Key words: Abused tissue, Complete denture therapy, Pre-prosthetic surgery

Introduction

The basic objectives of complete denture prosthodontics are the restoration of function, facial appearance and the maintenance of the patient's health¹. However, epidemiological studies of the edentulous population has shown that most patients with complete dentures have pathologic tissue changes that require treatment and these changes have little relation to a patient's perception of denture success or personal oral health status². The success of a new denture requires the support of healthy tissues. Any soft tissue or hard tissue changes should be minimized before any changes are made and the definitive treatment should be guided towards preservation of oral tissues. A comprehensive clinical examination and accurate dental history are essential to identify problems and take necessary corrective action. Recovery of abused tissue requires tissue rest, tissue conditioning and if not successful requires surgical intervention³. The soft tissue growth can be painless and the patient is often unaware of its presence. Sometimes, however, where the mass of hyperplastic tissue is large, patients may show concern — often about the possibility that such a 'growth' is malignant⁴.

Case report

A male patient 57 years of age with no significant medical history presented with a chief complaint of broken upper complete denture. The patient was also concerned about the tissue growth in the right buccal vestibule and was afraid of cancer. He was wearing the dentures for the past 5 years. The dentures were fabricated within 7 days after the extraction of natural teeth.

On intra-oral examination there was severe residual ridge resorption in both the upper and lower arches. The premaxillary region had flabby redundant tissue and slight redness suggesting of chronic inflammation (Fig 1). There was reactionary growth (epulis fissuratum) in the right buccal vestibule of the maxilla and in the left vestibule the mucosa was red and swollen. The lower ridge had flat appearance (Fig 2). However, there was no inflammatory change in the lower ridge. The lower denture retention and stability was compromised and the lower denture seemed to be floating in the mouth and upper denture also had limited retention, stability and support.

Correspondence

Dr. Dinesh Sharma Bhusal, Resident, NAMS, Bir Hospital, Mahabouddha, Kathmandu, Nepal
E-mail: drdsbhusal@yahoo.com

On examination of the complete dentures the borders of both the dentures were thin and the lower denture was under extended in the distolingual region. The mesiodistal span of denture teeth was in excess dimension encroaching upon the tuberosity region in maxilla and incline of residual ridge in mandible. (Fig 3 and Fig 4).The tissue surface of denture did not have sufficient details which would aid in retention. The upper teeth seemed to be out of the ridge buccally (Fig 5) which may have led to the pathological changes in the oral tissues and probably the fracture of the upper denture. The hygiene of the dentures was good indicating that the patient was concerned about the care of the dentures.

The vertical dimension of occlusion was satisfactory which suggested that the initially the vertical dimension of occlusion (VDO) could have been more at the insertion since there was significant resorption of the both the residual ridges.

Tissue rest was advised for a week by instructing the patient to leave the dentures in the hospital. After 1 week, only the inflammatory components had resolved but the hyperplasia of the border tissues and flabby ridge were the same. Surgery was done to remove the hyperplastic tissue present at the border areas and flabby tissue in the premaxillary region. The excised tissues (Fig. 6) were sent for histologic evaluation for further examination and also to rule out any malignancy. The histological report suggested signs of chronic inflammation, parakeratosis and acanthosis (Fig 7)

The oral tissues were allowed to heal and preliminary impression was planned 1 month after surgery. After one month the tissues appeared healthy with no signs of inflammation and without any flabby tissues in the premaxillary region (Fig 8)

Preliminary impressions of both the arches were made using irreversible hydrocolloid impression material. The lower custom tray was extended to utilize the retromylohyoid area for proper denture support and seal. The wax spacer of 1.5 mm was used in upper and lower custom tray and additional layer of wax was added in the premaxillary region. Border moulding was done with Greenstick compound. Large numbers of relief holes, especially in the premaxillary region was made before final impression procedure; low seating velocity was utilized to minimize pressure⁵ on the oral tissues. Both the upper and lower impressions were made using zinc oxide eugenol impression paste.

After processing, the dentures appeared to have greater surface area than the old ones and the mandibular denture had extended distolingual flanges. Both the dentures had reduced mesiodistal occlusal span. (Fig. 9 and 10). The borders were thick and the teeth were more on the ridge providing space for the buccal corridor. Diastemas provided the characterization as per the patient wish. The retention, stability and support of the denture were superior to that of the one he was wearing prior to the treatment (Fig 11). There was proper intercuspatation in centric relation (Fig 12). The patient was comfortable and happy with the new dentures (Fig 13)

The patient was asked to attend the hospital at 1day, 1 week and 1 month after the insertion for evaluation. Minor adjustments were done on the sore spots and minor chair-side occlusal adjustments were made and recalled after 3 months. On intraoral evaluation after 3 month post-insertion, the oral tissues showed no signs of inflammatory reactions (Fig 14). The dentures were comfortable and retentive. He was further educated regarding denture care, oral hygiene and the importance of recall visits.

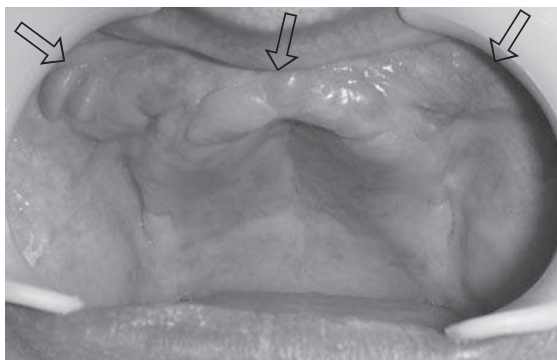


Fig 1:Initial presentation of upper arch with inflammation, hyperplasia and flabby ridge

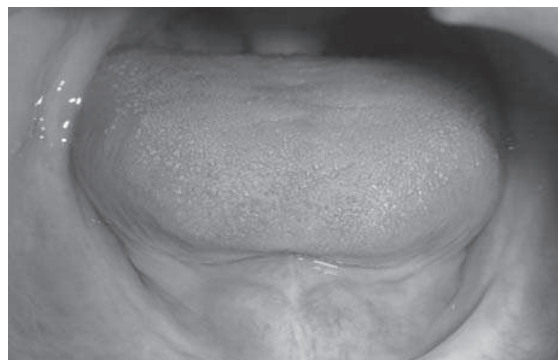


Fig 2:Initial presentation of lower arch

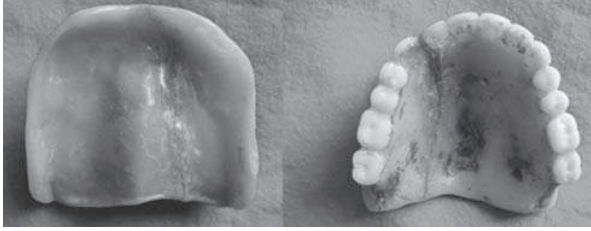

Fig 3: Tissue surface and occlusal surface of upper dentures at initial presentation; fractured fragments of upper denture cemented with cyanoacrylate cement

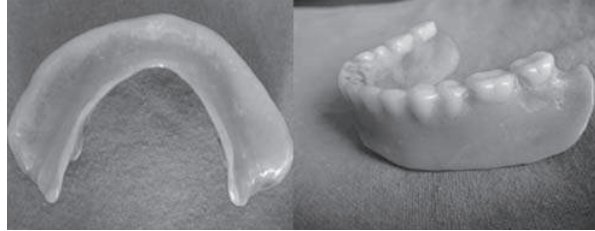


Fig 4: Initial presentation of the lower denture

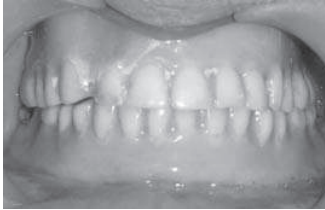

Fig 5: Intraoral view of old dentures

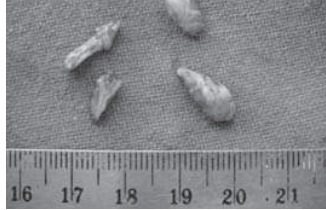


Fig 6: Presentation of the fibrotic and flabby tissues

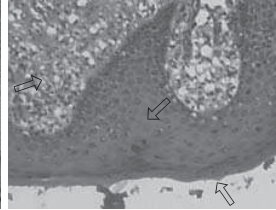


Fig 7: Parakeratosis, acanthosis and chronic inflammatory cells

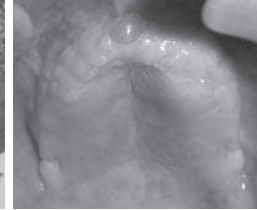


Fig 8: Intra oral presentation of upper arch after 1 month of surgery

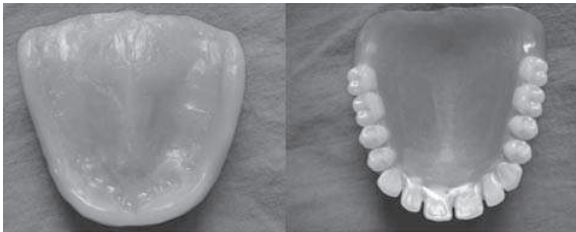

Fig 9: Tissue and occlusal surface of new upper denture without teeth over the tuberosity

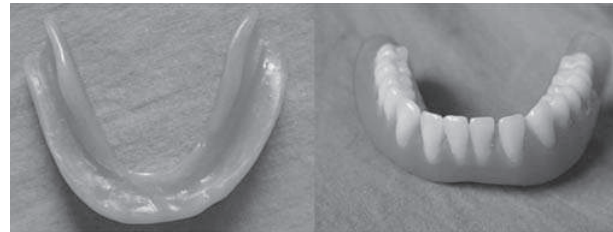

Fig 10: Newly formed lower denture with extended distolingual flanges

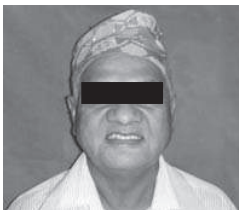

Fig 11: Extraoral view wearing old dentures (no buccal corridor)

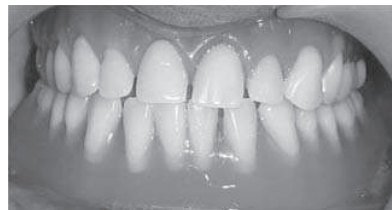

Fig 12: Proper intercuspation in centric relation and characterization

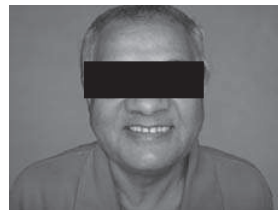


Fig 13: Extraoral view after the insertion of new dentures

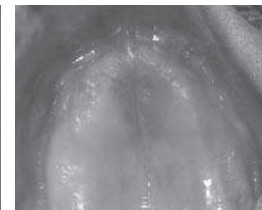

Fig 14: Maxillary arch after 3 months of post insertion

Discussion

Complete dentures are foreign objects in the oral cavity that are accepted and tolerated by the tissue to a certain degree⁵. However, ill-fitting complete dentures can alter the character, condition and form of the underlying oral tissues. It has also been suggested that there might be an association between oral carcinoma and chronic denture irritation, but no indisputable evidence appears to exist⁶. These effects can be divided into direct and indirect sequelae. To the first group belong residual

ridge resorption and mucosal reactions, such as denture stomatitis, denture irritation hyperplasia, traumatic ulcers, and "flabby ridges"⁶. Fibrous tissue hyperplasia has been reported to occur in 5% to 10% of jaws fitted with dentures, with the higher figure for the maxillae⁷. An epulis fissuratum appears as redundant tissue in the alveolar vestibule. Flabby ridges have been observed in up to 24% of edentulous maxillae and in 5% of edentulous mandible, and in both jaws most frequently

in the anterior region⁶. Indirect sequelae are related to the great changes in masticatory function in complete denture wearers compared with dentate subjects.

Abnormalities caused by local, mechanical, or systemic factors must receive proper diagnosis and treatment⁸. The management of abused tissue should always start with conservative approach like tissue rest, massage, and tissue conditioners. Rest for the denture supporting tissues can be achieved by removal of denture from the mouth for an extended period or the use of temporary soft liners inside the old dentures⁹. Oral massage can stimulate the tissues by increasing the vascularity and tissue rest omits the irritating stimulus thus can help restore the health of the tissue¹⁰. If the non-invasive treatments fail to achieve optimal tissue health then pre-prosthetic surgery may be needed to improve the denture bearing areas. It is also very important to emphasize on a good nutritional program patients especially for geriatric patient whose metabolic and masticatory efficiency may be compromised⁹. Treatment of an epulis fissuratum or a fibroepithelial polyp requires complete surgical excision, and after surgery, the dentures must be refabricated, rebased or relined¹¹. It is essential that the mouth is in an optimal state of health prior to commencing prosthetic treatment, and failure to achieve this may well produce an unsatisfactory treatment result⁴. Excessive thickness of the mucosa causes movement during the use of a complete denture, which may impede a proper stability and encourage the hyperplasia of the fibrous connective tissue¹². There are different impression techniques for flabby ridges. Zafrulla Khan has described a technique where window is created in the impression tray in the area of flabby ridge and impression plaster is painted in the area¹³. Using spacer and relief holes and utilizing low seating velocity can also decrease the pressure in the recording tissues^{14, 15} and we have utilized spacer, relief holes and low seating velocity in our impression making procedures.

In our patient, there were inflammatory and hyperplastic changes as a result of faulty prosthesis and the result shows that properly constructed prosthesis in the healthy oral tissues improves the condition.

Conclusion

Improperly constructed prosthesis especially in the "green ridge" (ridge immediately after extraction) can be the cause for pathological changes in the oral tissues which can lead to the patient dissatisfaction, discomfort and fear of malignancy. Proper history and pre-prosthetic treatment followed by right treatment plan and execution

will lead to comfortable, esthetic, functional and tissue friendly prosthesis.

References

1. Sheldon Winkler. Essentials of complete denture prosthodontics. Second edition, Delhi, A.I.T. B.S.;2009.p. xiii.
2. Bloem TJ, Razzog ME. An index for assessment of oral health in the edentulous population. *Spec Care Dentist* 1982;2(3):121-124.
3. DandoWE, Barker WS. Tissue conditioning. *Clinical Update* 2000;22(5):11-12.
4. McCord JF, Grant AA. Pre-definitive treatment: Rehabilitation prosthesis. *Br Dent J* 2000 Apr;22: 188(8):419-24.
5. Kapur K, Shklar G. The effect of complete dentures on alveolar mucosa. *J Prosthet Dent* 1963;13(6):1030-37.
6. Gunnar E. Carlsson. Clinical morbidity and sequelae of treatment with complete dentures. *J Prosthet Dent* 1997;79:17-23.
7. Xie Q, Närhi TO, Nevalainen JM, Wolf J, Ainamo A. Oral status and prosthetic factors related to residual ridge resorption in elderly subjects. *Acta Odontol Scand* 1997;55:306-13.
8. Salinas TJ. Treatment of edentulism: optimizing outcomes with tissue management and impression techniques. *J Prosthodont* 2009;18(2):97-105.
9. George A. Zarb, S. Ross Bryant. Editors. Preprosthetic Surgery: Improving the Patient's Denture - Bearing Areas and Ridge Relations. In: *Prosthodontic Treatment for Edentulous Patients*. 12th Edition., St. Louis, Mosby 2004. p.100-102.
10. Iuliana Babiuc et al. Correct complete denture rehabilitation, a chance for recovering abused tissues. *Rom J Morphol Embryol* 2009;50(4):707-12.
11. Michael Turner, Leila Jahangiri, Jonathan A. Ship. Hyposalivation, xerostomia and the complete denture A systematic review. *J Am Dent Assoc* 2008;139(2):146-50
12. Desjardins RP, Tolman DE. Etiology and management of hypermobile mucosa overlying the residual alveolar ridge. *J Prosthet Dent* 1974;32(6):619-38.
13. Z Khan, JH Jagers, JS Shay. Impressions of unsupported movable tissues. *J Am Dent Assoc* 1981;103(4): 590-92.
14. T Paul Hyde, Helen Craddock, Paul Brunton. The effect of seating velocity on pressure within impressions. *J Prosthet Dent* 2008;100:384-89.
15. Osamu Komiyama, Hiroyuki Saeki, Misao Kawara, Kihei Kobayashi, Shigeo Otak. Effects of relief space and escape holes on pressure characteristics of maxillary edentulous impressions. *J Prosthet Dent* 2004;91:570-6.